

SADA

THE SOUTH AFRICAN
DENTAL ASSOCIATION



A Guro mask from the Ivory Coast

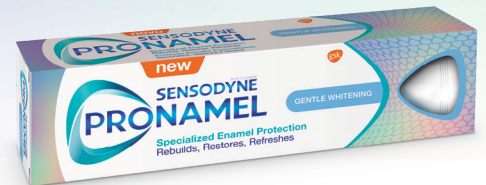(Thanks to Marna Schoeman for sharing it from her collection.)

The hand carved Guro masks of the Ivory Coast represent the spirit of Gu, the wife of Zamble, a supernatural being. All masks are individually carved and coloured and no two are ever the same, however they all have a number of similarities. They all have a combination of human and animal traits such as horns or bills from large billed birds which give them magical spiritual powers, and protect the owner as well as the tribe. They were worn during customary ceremonies, funerals, animal sacrifices and weddings. Today the people honour their ancestors with traditional dances and wear the masks as a symbol of respect and loyalty to their past.

new



HELPS REBUILD
& STRENGTHEN
YOUR ENAMEL



Specialized Enamel Protection
Rebuilds, Restores, Refreshes

**No.1 DENTIST RECOMMENDED
BRAND FOR SENSITIVE TEETH***



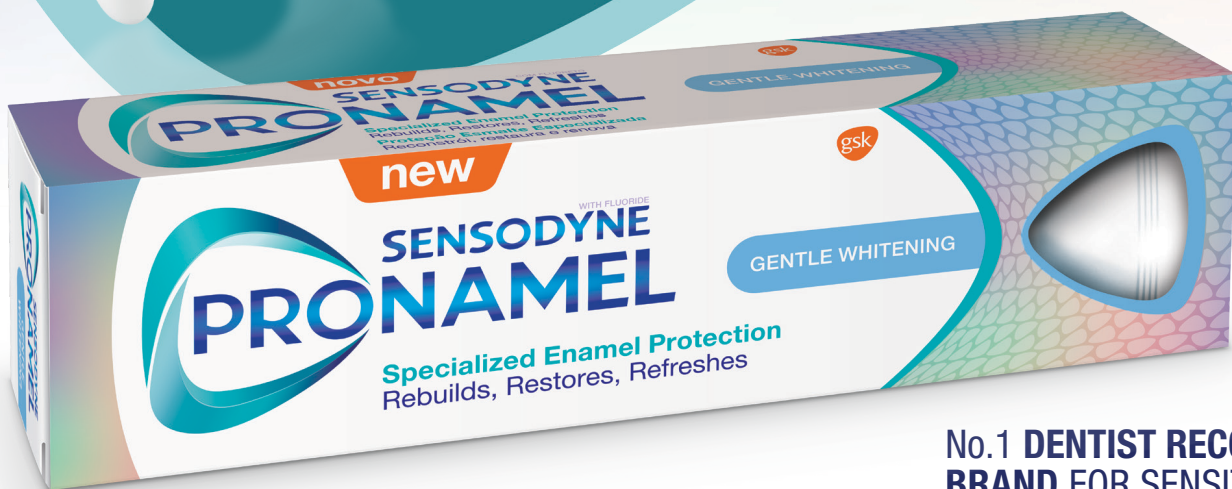*IPSOS Expert Performance Tracking 2020

GlaxoSmithKline Consumer Healthcare South Africa (Pty) Ltd. 57 Sloane Street, Bryanston, 2021. Reg. No.: 2014/173930/07. For any further information, including safety information, please contact the GSK Hotline on +27 11 745 6001 or 0800 118 274. Trademarks are owned by or licensed to GSK group of companies. Refer to carton for full use instructions. Promotion Number: PM-ZA-SENSO-21-00017.

new



HELPS REBUILD & STRENGTHEN YOUR ENAMEL



No.1 DENTIST RECOMMENDED BRAND FOR SENSITIVE TEETH*



Specialized Enamel Protection

Rebuilds, Restores, Refreshes

*IPSON Expert Performance Tracking 2020
GlaxoSmithKline Consumer Healthcare South Africa (Pty) Ltd. 57 Sloane Street, Bryanston, 2021. Reg. No.: 2014/173930/07. For any further information, including safety information, please contact the GSK Hotline on +27 11 745 6001 or 0800 118 274. Trademarks are owned by or licensed to GSK group of companies. Refer to carton for full use instructions. Promotion Number: PM-ZA-SENSO-20-00123

EDITORIAL OFFICE

Managing Editor

Prof NH Wood

Editorial Assistant

Mr Dumis Ngoepe

Email: ngoeped@sada.co.za

Sub-editors

Prof N Mohamed

Prof P Owen

Prof L Sykes

Prof J Yengopal

Please direct all correspondence to:

South African Dental Association

Private Bag 1, Houghton 2041

Tel: +27 (0)11 484 5288

Fax: +27 (0)11 642 5718

Email: info@sada.co.za

Editorial Board

Dr P Brijlal: University of the Western Cape

Prof T Dandajena: Private Practice USA

Prof W G Evans: University of the Witwatersrand

Dr H Gluckman: Private Practice

Dr M Hellig: University of the Witwatersrand

Prof B Kramer: University of the Witwatersrand

Prof AJ Louw: University of the Western Cape

Dr N Mohamed: University of the Western Cape

Prof J Morkel: University of the Western Cape

Prof MPS Sethusa: Sefako Makgatho Health Sciences University

Prof L Shangase: University of Pretoria

Prof L Sykes: University of Pretoria

Prof AW van Zyl: Private Practice

Prof NH Wood: Sefako Makgatho Health Sciences University

SADA OFFICE BEARERS

National Council

President: Dr RR Naidoo

Vice-President: Dr APL Julius

SADA Board of Directors

Chairperson: Dr R Putter

Vice-chairperson: Dr N Osman

Dr SJ Swanepoel

Dr SY Pieters

Dr FC Meyer

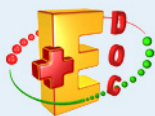Dr EK Naidoo

Mrs C Wessels

Mr H Keshave

Mr KC Makhubele (CEO)

Published by:



On behalf of:



CONTENTS

FRONT COVER PICTURE

“Wear your mask” - *LM Sykes, NH Wood*

1

EDITORIAL

A new year brings renewed hope - *NH Wood*

2

COMMUNIQUE

Trends and lessons from the Mediation Report - *KC Makhubele*

3

RESEARCH

Voluntary Counselling and Testing for HIV in the dental setting: Knowledge, attitudes and practices of oral health care workers in eThekweni district, KwaZulu-Natal - *S Balwanth, S Singh*

6

CASE REPORT

Orthodontic repositioning of traumatically intruded permanent incisors - A report of three cases - *H Singh, M Mittal, P Sharma, A Kumar, P Kapoor*

14

REVIEW

A comparison of root canal transportation and centering ability between WaveOne® Gold and Protaper Next® files, using micro-computed tomography - *A Gajoum, E Patel, IE Munshi, S Tootla*

22


Factors influencing apical debris extrusion during endodontic treatment - A review of the literature

- *N Predin Djuric, PJ van der Vyver, M Vorster, ZI Vally*

28

Our Front Cover for this Issue...

The theme for the Front Cover of the South African Dental Journal this year showcases various types of masks. Masks have been admired and worn throughout the world for centuries and play an integral part of many activities including customary rituals, cultural events, battles, entertainment, and for protection. The cover for February features a hand carved Guro mask of the the Ivory Coast. Read more on page 1.



A Guro mask from the Ivory Coast

(Thanks to Marna Schoeman for sharing it from her collection)
The hand carved Guro masks of the Ivory Coast represent the spirit of Gu, the wife of Zamble, a supernatural being. All masks are individually carved and coloured and no two are ever the same, however they all have a number of similarities. They all have a combination of human and animal traits such as horns or bills from large billed birds which give them magical spiritual powers, and protect the owner as well as the tribe. They were worn during customary ceremonies, funerals, animal sacrifices and weddings. Today the people honour their ancestors with traditional dances and wear the masks as a symbol of respect and loyalty to their past.

SADA OFFICE BEARERS**Chairpersons of Board Sub-Committees**

Audit & Risk Committee:	Dr N Osman
Strategy, Ethics & Remuneration Committee:	Dr SY Pieters
Dental Practice Committee:	Dr SJ Swanepoel

Chairperson of DDF Board of Trustees

Dr B Beilinson

PRODUCTION OFFICE

E-Doc CC,
a Division of Life-Long Learning Solutions CC
Tel: +27 (0)10 020 1013

Publisher and Project manager

Mr René Smulders

GENERAL AND ADVERTISING ENQUIRIES

Mr René Smulders
Email: rene@edoc.co.za

Design and Layout

Ms Reine Combrinck
Email: production@edoc.com

Website smalls advertising / CPD Enquiries and**Member contact detail update**

South African Dental Association
Tel: +27 (0)11 484 5288
Email: info@sada.co.za

CLINICAL WINDOW

What's new for the clinician? - Excerpts from and summaries of recently published papers - *V Yengopal* 37

RADIOLOGY CASE

Maxillofacial Radiology 187 - *CJ Nortjé* 41

ETHICS

Mandatory COVID-19 vaccination for oral health professionals (OHPs) - Ethical appraisal - *LM Mtolo, PD Motloba, NH Wood* 42

CPD

CPD questionnaire 46

AUTHOR GUIDELINES

Instructions to authors and author's checklist 49

CLASSIFIEDS

www.sada.co.za - Small advertising placement procedure and rules 53

Editorial, Advertising and Copyright Policy

Opinions and statements, of whatever nature, are published under the authority of the submitting author, and the inclusion or exclusion of any medicine or procedure does not represent the official policy of the South African Dental Association or its associates, unless an express statement accompanies the item in question. All articles published as Original Research Papers are refereed, and articles published under Clinical Practice or Reviewed Notes are submitted for peer review.

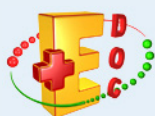The publication of advertisements of materials or services does not imply an endorsement by the Association or a submitting author, should such material feature as part of or appear in the vicinity of any contribution, unless an express statement accompanies the item in question. The Association or its associates do not guarantee any claims made for products by their manufacturers.

While every effort is made to ensure accurate reproduction, the authors, advisors, publishers and their employees or agents shall not be responsible, or in any way liable for errors, omissions or inaccuracies in the publication, whether arising from negligence or otherwise or for any consequences arising therefrom.

Accredited by the Department of Education

SADJ is published 10 times a year by E-Doc CC, a Division of Life-Long Learning Solutions CC, on behalf of The South African Dental Association. © 2021 Life-Long Learning Solutions CC.

Published by:



On behalf of:



SADA
THE SOUTH AFRICAN
DENTAL ASSOCIATION

“Wear your mask”

SADJ February 2021, Vol. 76 No. 1 p1

LM Sykes¹, NH Wood²

The current pandemic has made the wearing of masks a “necessary, if not life-saving, evil”. However, masks have been admired and worn throughout the world for centuries and play an integral part of many activities including customary rituals, cultural events, battles, entertainment, and for protection. They may hide identities, reveal certain personality traits, suggest moods, or act as a barrier between the wearer and the outside world. Masks and mask making has a striking number of similarities to dentistry, and so it seemed fitting to dedicate this year’s cover pages to various types of masks.

Both masks and dental restorations may vary in form ranging from very simple to highly complex. Both can be made from a variety of materials including (historically) wood, bone, ivory, plant fibres, metals, ceramics, and synthetic compounds. They can be produced using a number of different tools and techniques, to provide surface finishes that are rugged, simplistic, smooth or intricately carved and detailed. Some may even be adorned with added “cosmetic bling” according to the tastes and customs of the wearer.

Their morphological elements are usually derived from natural forms and may be near identical replicas of the innate features, or can be reconstructed to alter the wearer’s image quite dramatically. The latter can deviate to the extent of providing some with a whole new identity.



Masks (and dental restorations) are made by professional artisans or sculptors (clinicians), are manufactured within certain bounds, following prescribed well-established steps (evidence based dentistry), and using tried and tested procedures and techniques. If not followed, the artist could bring upon themselves severe censure from their allied social group. However, there is always a permitted degree of freedom for artistic expression, and the artist is encouraged to add certain “vital or aesthetically pleasing” features to their work. Those who are able to do this became highly sought after and well respected in their field.

Traditionally it was believed that the spiritual powers of the mask manufacturer were conferred to the mask, and lived within it. In order for these spirits to provide benefits and protection to the wearer there needs to be a close and harmonious relationship between the maker, the work, and the recipient. How wonderful it would be for us as a profession if our treatment, restorations, and work ethic could mimic the artistry and spirituality of the masks and their creators.

We too could provide our patients with a number of benefits including more pleasing smiles, confidence, and perhaps even brighter personalities. This year lets all strive to bring the beneficent spirits within us to life in all of our daily lives, work, and activities.

Leanne M Sykes: BSc, BDS, MDent, IRENSA, Dip Forensic Path, Dip ESMEA, Head of Department of Prosthodontics, University of Pretoria, South Africa. Email: leanne.sykes@up.ac.za
Neil H Wood: Managing editor. Email: neil.wood@smu.ac.za

A new year brings renewed hope

SADJ February 2021, Vol. 76 No. 1 p2

NH Wood
Managing Editor of the SADJ



We have seen a decline over the past year in the provision of oral healthcare services to our patients and to our communities. The efforts to curb the spread of the SARS-CoV-2 virus inadvertently left a void in what would have been the normal standard of care. However, we know by now that pre-Covid normality has been relegated to the history books.

The roll-over effect of the lack of oral health care provision cannot yet be determined, but I fear that there may be dire consequences for some of our vulnerable patients, more so in our vulnerable communities.

Access to oral healthcare for many communities was already a challenge already pre-Covid, often necessitating travel to clinics or hospitals far from their homes. Given the restrictions during the various lockdown stages, fear of contracting the virus and other contributing factors, we have seen a further decline in the overall attendance numbers of patients seeking urgent or emergency care.

The fact that many patients could not attend to regular check-up visits, to receive minor procedures or preventive interventions, or to maintenance programs, raises the serious concern that we may see a peak in emergency procedures over the next few months. A detailed study of our own populations is needed to quantify the sequelae of the lockdown, and to assist in designing strategies to provide routine care and prevention, even to the most isolated patients in our society.

However, many of the changes we now see in our own practices and clinics have impacted the profession favorably, most notably within infection control, communication and personal interaction, and also on the teaching and training of various oral healthcare personnel. If we

embrace change and sustain the positive aspects thereof, it will have a meaningful impact on the further growth and development of oral healthcare in South Africa.

It is up to us to take this opportunity to evolve our approaches to oral healthcare, and to develop our prevention-centric stance even further. Irrespective of the setting that we practice in, there are moments when we have the ability to take positive action and contribute to the greater good within the context of oral health care. We all hold a social responsibility towards society.

Our cover page theme for this year relates to masks, thought to be befitting of the pandemic the world is currently struggling with. We will feature a diverse array of masks, all of which serve their own purpose and worn with different intentions. We also welcome submissions from our readers of masks that have significant meanings/symbolism attached.



Although we are still facing serious challenges, I wish you well for this year, and may 2021 be prosperous to all. Please enjoy the February 2021 issue of the SADJ filled with interesting content, with thanks also to our regular contributors.

Footnote

Please be reminded to register on our online platform at <https://journals.assaf.org.za/index.php/sadj/index>

Trends and lessons from the Mediation Report

- for the period 1 July 2020 - 30 September 2020

SADJ February 2021, Vol. 76 No. 1 p3 - p5

KC Makhubele
Chief Executive Officer, SADA



In the past year, I have been spending time reading and observing the trends regarding the type and nature of cases that our dental mediator receives. I am of the firm view that if one studies this, you may learn one or two things that may improve the way you interact with patients and avoid many issues associated with an unhappy patient.

I am publishing the Mediation Report for the period 1 July 2020 – 30 September 2020, as presented by our dental mediator, Dr J Barnard.

INTRODUCTION

It is with pride that I present the mediation report for the period 1 July 2020 to 30 September 2020 to the national council. Firstly, I want to thank SADA for the opportunity to take responsibility for the complaint resolution service

during 2020 and the continuous backup and support when needed. Special thanks to Punkaj, KC and Dr WP van Zyl for their constant assistance and support. Without them, it would not be possible to run an efficient and professional service.

During the third quarter, the mediation office received numerous patient complaints and inquiries related to PPE charges. Dentists charged anything between R50.00 and R440.00 per visit for PPE, often without explaining the need for these charges and the costs involved before the patient's appointment. Complaints varied from overcharging for PPE to concerns about inadequate infection control. Thankfully the dust has settled, and things are slowly returning to normal.

Let's look at the statistics for the period 1 July 2020 - 30 September 2020.

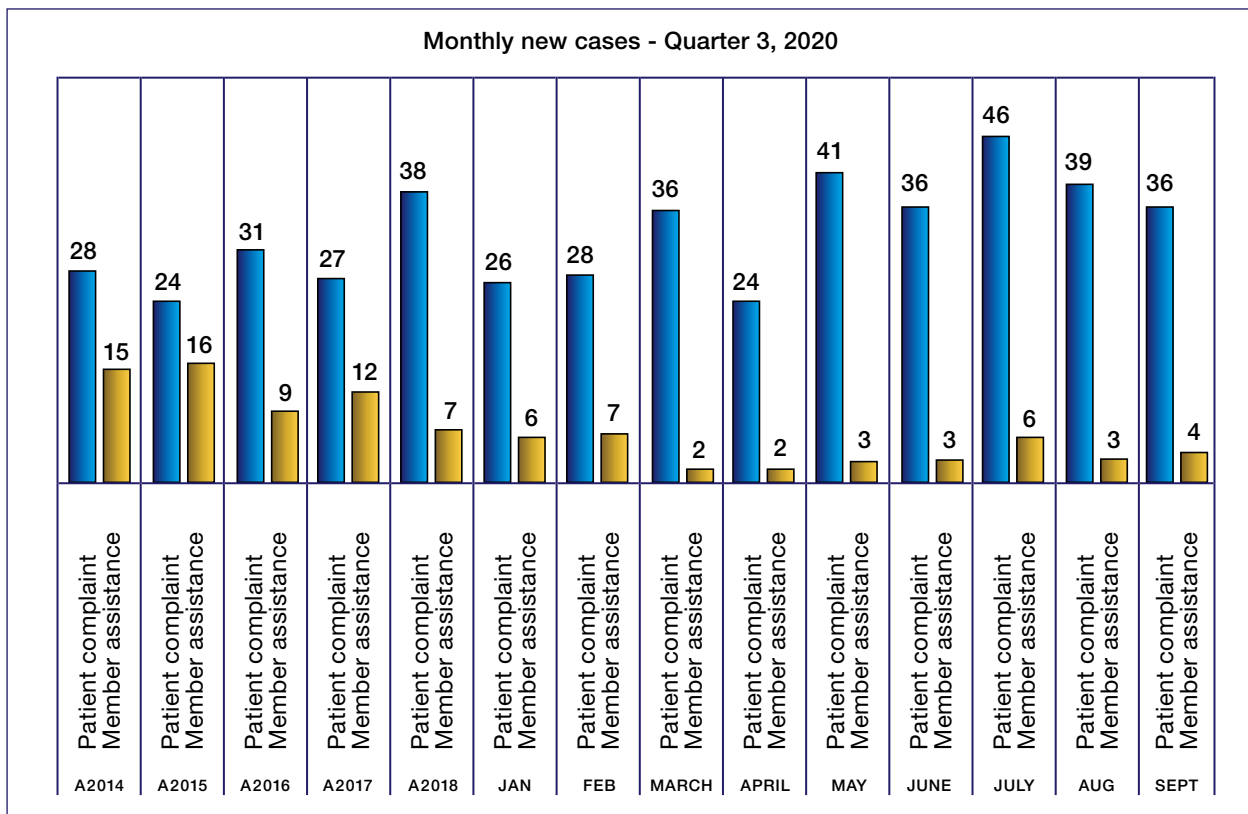


Figure 1. Monthly new cases 1 July 2020 - 30 September 2020.

Analysis of Figure 1

The self-explanatory chart above illustrates the number of new cases accepted monthly in this period (1 July 2020 - 30 September 2020) compared to monthly averages of the previous five years. An increase in the number of patients contacting SADA in 2020 compared to the last four years is noted. July has been busier than usual, mostly with PPE related inquiries and complaints.

Analysis of Figure 2

The majority of new cases accepted in this period (1 July 2020- 30 September 2020) were fee or medical aid related issues (42%). The increase in complaints in this category is mostly because of the PPE related issues raised earlier.

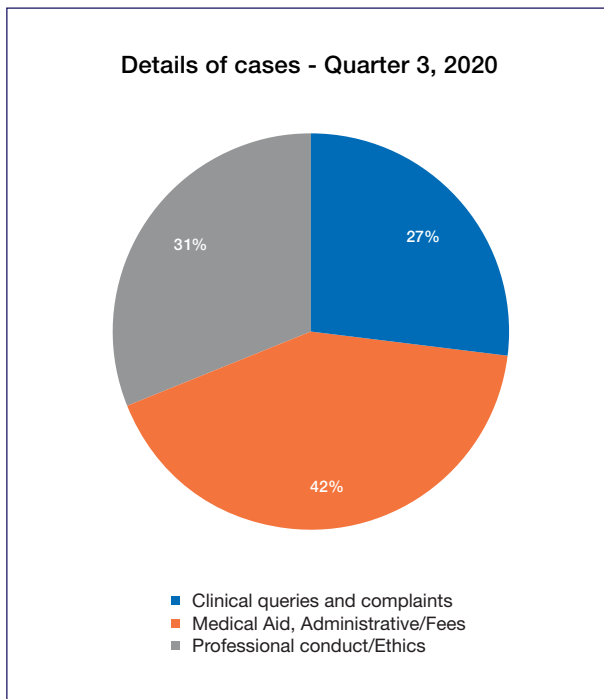


Figure 2. Nature of new cases received 1 July 2020 - 30 September 2020.

In only 27% of the cases accepted in this period, the patient complained about the perceived quality of the clinical treatment. In these cases, the clinician either failed to achieve the desired therapeutic goals, meet the pre-operative expectations of the patient, or failed to manage postoperative complications.

Most practitioners or their staff are aware of the patient's disappointment but fail to address the needs and expectations of the patient at the practice level.

This results in a relationship breakdown causing the patient to phone SADA or report the matter to the HPCSA.

During the third quarter (1 November 2019 - 30 June 2020), a total of 121 patients contacted the Mediator with their complaints and inquiries. A total of 13 dentists/SADA members contacted the Mediator for assistance with a patient complaint.

Of the 134 cases accepted, only 69 needed some form of mediation. The remaining 65 cases just required advice, reassurance or information. Mostly about treatment codes, the dentist's fees, treatment options and postoperative complications.

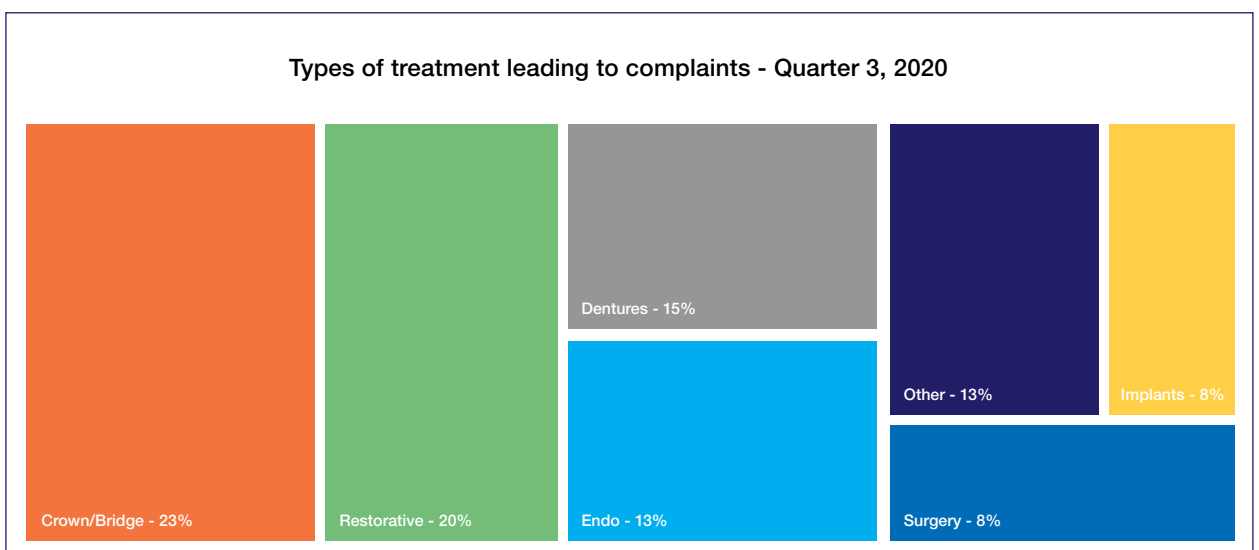


Figure 3. Types of treatment leading to complaints - Quarter 3, 2020.

Analysis of Figure 3

The majority of cases in Quarter 3 is associated with crown and bridge treatment (23%), and routine restorative treatment (20%). These figures compare well with previous periods.

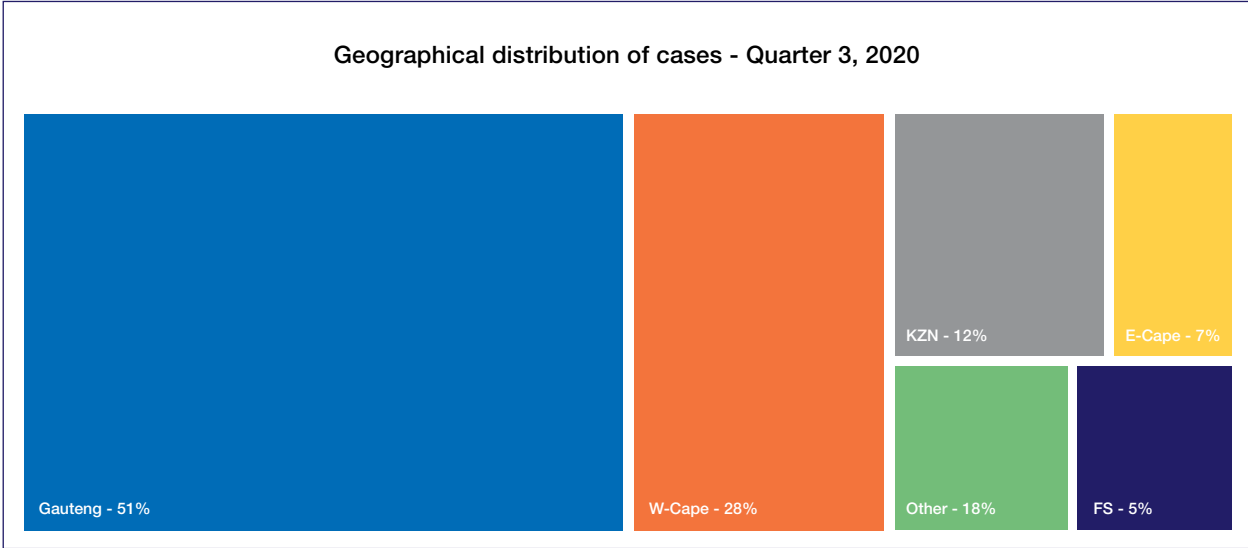


Figure 4. Geographical distribution of cases - Quarter 3, 2020.

Analysis of Figure 4

In this period most cases originated in Gauteng (51%), followed by Western Cape (28%) and KZN (12%).

In most cases, complainants chose English as a preferred language to communicate (49%), closely followed by Afrikaans (38%). The remaining 13% of complainants would have preferred to communicate in an African language.

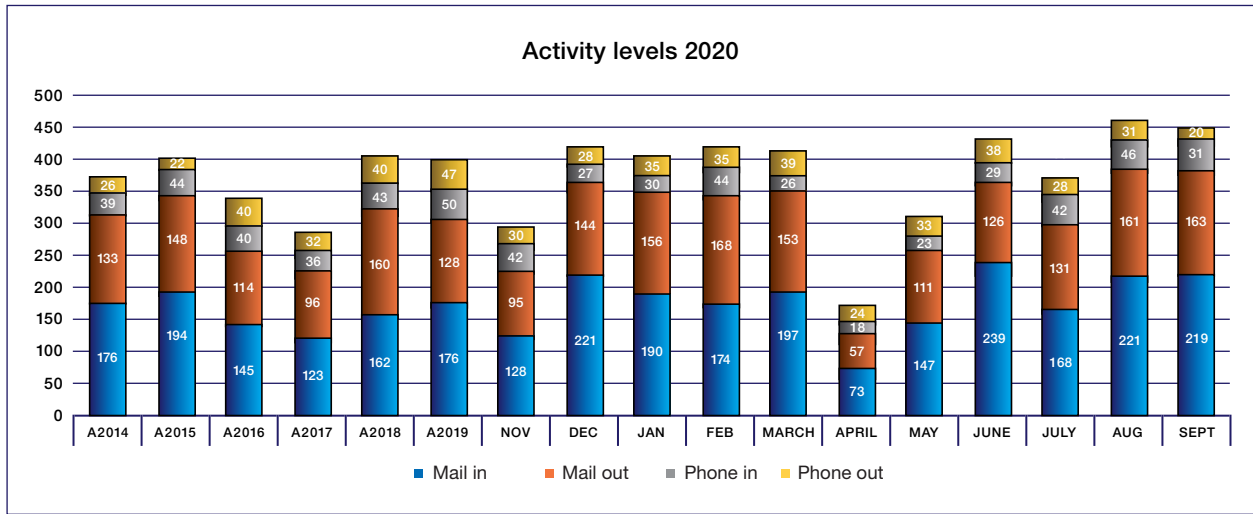


Figure 5. The monthly activity of the Mediator - Quarter 3, 2020.

Analysis of Figure 5

This chart reflects the monthly activity levels of the Mediation office during 2020 compared to the monthly averages of the previous five years. The activity levels and workload of the Dental Mediator office in 2020 have increased compared to the last five years. April has been unusually quiet as expected during the Level 5 Lockdown period.

I am pleased to report a successful period of mediation thanks to excellent cooperation from colleagues and patients.

Voluntary Counselling and Testing for HIV in the dental setting: Knowledge, attitudes and practices of oral health care workers in eThekweni district, KwaZulu-Natal

SADJ February 2021, Vol. 76 No. 1 p6 - p11

S Balwanth¹, S Singh²

ABSTRACT

Introduction

Oral health care workers are frequently at the forefront in recognizing oral manifestations of the Human Immunodeficiency Virus (HIV) and can therefore play a key role in screening and early detection of HIV in dental patients.

Aim and objectives

This study assessed oral health care workers' knowledge, attitudes and possible practices in Voluntary Counselling and rapid HIV testing (VCT) in the dental workplace in eThekweni district, KwaZulu-Natal so as to determine their understanding and support for these services.

Methods

This was a cross-sectional, descriptive study. A total of 120 questionnaires were distributed to oral health workers located in private and public dental settings in eThekweni district. One hundred (n=100) completed questionnaires were retrieved, yielding a response rate of 83%.

Results

The majority of participants (82%) reported that HIV testing and counselling did not occur in their workplace. Participants (87%) also indicated to have not been trained to perform HIV testing.

Sixty-six participants (66%) reported willingness to implement HIV testing in their respective dental workplace. Less than half of the study population (41%) were "unsure" regarding the accuracy of rapid HIV testing.

Conclusion

Participants reported inadequate knowledge and practice of VCT. Participants had positive attitudes towards VCT implementation in the dental setting, provided that adequate training and support was available from the KwaZulu-Natal Department of Health.

Keywords

Rapid HIV testing, dental workplace, oral health care workers.

INTRODUCTION

Oral health care workers' knowledge, attitude and practices towards HIV testing and counselling, could reflect their understanding of the importance of early HIV screening in the dental workplace and in turn, play a role in contributing to improved management of the HIV crisis in KwaZulu-Natal. The prevalence of the Human immunodeficiency virus and Acquired immunodeficiency syndrome (HIV/AIDS) in South Africa, is high with 20.4% of the population being affected.¹

Sadly, almost 18.23% of these affected populations are located in KwaZulu-Natal.² HIV testing is considered an essential strategy in addressing the disease and provides an opportunity for oral health care workers to offer early HIV detection, and referral pathways as part of a comprehensive care package.³ The oral health care worker is at the forefront of recognizing oral manifestations of HIV, promoting rapid HIV testing, and curbing the detrimental effects of the disease through support and education.⁴

Likewise oral health care workers need to have adequate knowledge to understand the pathogenesis of HIV infections and recognize the associated symptoms so that proper diagnosis and clinical management can be implemented as part of comprehensive patient care.^{4,5} Additionally, patient education and counselling rely heavily on the oral health care worker's understanding of HIV.⁵

VCT at the dental workplace

Oral lesions are often clinical markers of HIV and can be used to predict the progression of HIV to AIDS.^{6,7} A South

Author affiliations:

1. Sonam Balwanth: *BChD (UWC), MMed (UKZN), PG Dip Int Ortho (UWC)*, Discipline of Dentistry: School of Health Sciences, University of KwaZulu-Natal, Durban, South Africa.
2. Shenuka Singh: *BOH, MSc (Dent), PhD*, Postgrad Dip Health Res Ethics, Discipline of Dentistry: School of Health Sciences, University of KwaZulu-Natal, Durban, South Africa.
ORCID Number: 0000-0003-4842-602X

Corresponding author: Shenuka Singh

Discipline of Dentistry, School of Health Sciences, University of KwaZulu-Natal, Durban, South Africa.
Private Bag X54001, Durban, 4000.
Email: singhshen@ukzn.ac.za

Author contributions:

1. Sonam Balwanth: Primary author - 70%
2. Shenuka Singh: Secondary author - 30%

African study by Coogan et al. (2005) found that oral lesions may be present in up to 50% of HIV positive individuals and 80% of those with AIDS.⁶ The reported benefits of rapid HIV testing in the dental workplace, highlights a significant positive impact on patients visiting the dental sector.^{8,9,10} These reports reiterate the value and role of oral health care workers as an integral component in early HIV recognition and management.^{4,11,12}

Studies examining oral health care workers' knowledge, attitudes, perceptions and practice regarding VCT at the dental workplace, suggested that oral health care workers were generally supportive of extending HIV testing services to the dental setting. However, the lack of HIV testing training for oral health care workers was seen as a common limiting factor for the implementation of such services.^{4,13,14} Similarly, knowledge and skills related to VCT are pertinent to ensure proper testing and minimize possible false positive or false negative results.^{3,9}

Despite the potential value of implementing HIV testing and counselling services within the dental setting, there is a paucity of published evidence in South Africa to examine this strategy. Rapid HIV testing has not yet been implemented to the dental workplace in KwaZulu-Natal, thereby creating an opportunity to explore this strategy further. To our knowledge, this is the first study conducted in KwaZulu-Natal to determine oral health care workers preparedness or willingness to engage in such service delivery.

METHODS

This was a cross-sectional, descriptive study that assessed oral health care workers' knowledge, attitudes and practices regarding VCT services as part of HIV management. The study sample was drawn from the private and public sectors in eThekweni district. The study sites included private dental practices (n=60) and public health institutions (n=8) in eThekweni district. Systematic sampling technique was used to select dental practices from a list obtained from Medpages.

Given that the majority of oral health care workers are located in the private sector in KwaZulu-Natal, two oral health care workers were identified from each site. A sample size of 100 oral health care workers was seen as adequate (at 95% confidence level) to address the research question (personal communication with the statistician). A total of 120 questionnaires were distributed to the identified study sites and one hundred (n=100) completed questionnaires were retrieved, yielding a response rate of 83%.

The research instrument comprised a self-administered questionnaire which was validated by means of a pilot study which included (n=5) oral health care workers from eThekweni to clarify any ambiguity in the questions posed. The questionnaire included 22 items. The first part of the questionnaire focused on information such as gender, age group, profession, place of work and work experience. The second part included questions pertaining to knowledge and practices with respect to HIV testing training, referral of patients with HIV associated oral lesions, commonly observed HIV oral manifestations, HIV testing at the

dental workplace and knowledge of HIV testing. The third part of the questionnaire included questions related to oral health care workers' attitudes and perceptions of regarding HIV screening in the dental workplace.

A Likert 5-scale format of responses was used: 1-strongly agree, 2-agree, 3-not sure, 4-disagree and 5-strongly disagree to elicit respondents perceptions related to funding, resources, HIV testing, training and implementation of HIV testing in the dental workplace. The questionnaire consisted of closed ended and open-ended questions. Ethical clearance was obtained from the Biomedical Research Ethics Committee at the University of KwaZulu-Natal (BREC REF: BE400/17).

Participation was voluntary and written informed consent was obtained from all participants. The questionnaire was administered in English and isiZulu. Confidentiality and anonymity were maintained. Data was analyzed using SPSS version 24.0 (IBM Corp., USA). Univariate descriptive statistics, such as frequency and mean distribution were conducted for all variables.

The responses to the open-ended questions were grouped and emergent themes were examined and compared for possible associations. Inferential techniques included Pearson's chi squared test to assess a possible relationship between the independent variables (gender, age) and the dependent variables (perspectives on rapid HIV testing services in the dental workplace). A p-value <0.05 was considered to be statistically significant.

RESULTS

The total study population (n=100) comprised dental surgeons (69%), dental therapists (22%), oral hygienists (7%) and dental specialists (2%). Study participants were located in private dental practices (57%); public hospitals (34%), public clinics (6%) and mobile dental clinics (3%) (p<0.032). Participants (31%) were predominantly within the age distribution of 41 >years old while 54% of the study sample were male (Table 1).

Knowledge related HIV testing, rapid HIV testing, HIV training

Almost all participants (99%) indicated that HIV testing can be performed by obtaining the patient's blood sample (p<0.001). However, 37% of participants indicated that HIV testing cannot be conducted using saliva samples from patients. Additionally, 30% of participants were "unsure" as to whether HIV can be tested using urine samples from patients, while 54% of participants reported to be "unsure" of other methods of HIV testing apart from the ELISA and Western Blot method.

While the majority of participants (89%) reported to have heard of rapid HIV testing, 37% of participants believed that the accuracy of rapid HIV testing was not same as the ELISA and Western Blot method and 41 participants were "unsure" (Table 2). The majority of participants (83%) reported not to have received any training related to HIV counselling and testing. Almost all participants (94%) supported the idea that oral health care workers should be trained in HIV counselling and testing at the undergraduate level.

Positive attitudes and perceptions regarding voluntary counselling and testing for HIV in the dental workplace (Table 3)

The majority of participants (87%) reported that opportunistic routine HIV testing services in the dental workplace was a good idea. Almost all participants (98%) agreed that should HIV testing be offered to patients in the dental workplace, oral health care workers and staff should be adequately trained in VCT.

Participants (83%) believed that opportunistic HIV testing in the dental workplace could contribute to increased awareness around HIV infections and reduce possible stigma and rejection associated with the disease.

Participants (83%) also reported that HIV testing in the dental workplace was not a waste of medical resources and that such services could increase the possibility of patients seeking medical attention, which in turn could improve individual quality of life (93%).

Two thirds of participants (66%) reported willingness to implement HIV testing in their dental workplace while 80% believed that HIV testing is within the scope of dental practice. Additionally, the majority of participants (76%) were comfortable treating a suspected HIV positive patient and 81% of the participants did not feel at risk for contracting the disease.

Some participants reported reasons for willingness to implement HIV testing to the dental workplace, which included: early detection and effective management of HIV (n=13), awareness and knowledge of HIV status (n=10) and decreasing occupational risk of undiagnosed HIV positive individuals (n=3).

Sixty-seven participants (67%) reported that an HIV testing policy is required in the dental workplace prior to the implementation of a testing strategy.

Negative attitudes and perceptions regarding Voluntary Counselling and Testing for HIV in the dental workplace

Overall, 34 participants (34%) were not willing to implement HIV testing in their dental workplace, of which 26 participants were located in the private dental sector. Reported barriers or challenges in implementing HIV testing in the dental workplace (n=34, 34%) included: lack of suitability of HIV testing in the private practice due to time constraints and untrained staff (26.5%), the sensitive nature of HIV (5.9%), fear of stigmatization by patients (2.9%), no official HIV testing policy for the dental workplace (2.9%), and rapid HIV testing in the dental workplace was an additional stress (2.9%).

Overall, the majority of participants (83%) in this study indicated to not having sufficient staff to perform rapid HIV testing as well as pre-and post-testing counselling skills related to HIV testing. Participants that were not willing to undergo further training (18%) provided reasons such as "nearing retirement" (n=2), "not necessary in private practice" (n=2), "not interested in the training" (n=1) and "not a priority at the moment" (n=1).

Clinical practice related HIV identification, testing and patient referral

More than two thirds of participants (68%) indicated having a clinical workload of less than 5 patients per month that presented with possible HIV associated oral lesions. Some of the reported oral manifestations of HIV infections seen in patients presenting for dental management included oral candidiasis (63.3%), necrotizing ulcerative periodontitis (57.1%) and necrotizing ulcerative gingivitis (51%).

Eighty-two participants (82%) indicated that they did not conduct tests for HIV in patients presenting at their surgery/clinic. Almost all participants (98%) reported to have referred patients with suspected HIV related oral lesions for further confirmatory tests.

DISCUSSION

While the majority of participants (89%) reported to have heard of rapid HIV testing, only 18% indicated to have conducted rapid HIV testing in their dental setting. This finding is similar to that reported by Gumede in 2017, where the majority of participants in that study had heard of rapid HIV testing, yet only a few reported to have used rapid HIV testing.¹⁵ In the present study, almost all participants (82%) supported the need for training opportunities in HIV counselling and testing.

This finding is consistent with Ramphoma and Naidoo, who also reported that very few dentists in their study had comprehensive knowledge of oral HIV lesions and that almost all participants expressed the need for further knowledge and training in this regard.¹⁶ The majority of participants (68%) reported having a clinical workload of less than 5 patients per month that presented to their dental workplace with possible HIV associated oral lesions. Bhayat, Yengopal and Rudolph further add that oral lesions are useful clinical markers of HIV, but cautioned that the ability to recognize and diagnose these lesions are limited by the oral health care worker's skill and knowledge.¹¹

The uncertainty reported by more than half of the participants (54%) in this study with regards to the availability of other methods of HIV testing (apart from the ELISA and Western Blot method), could be an indicator of lack of continual holistic HIV education and information. Similarly, an investigation into HIV knowledge among undergraduate dental students in South Africa, showed acceptable knowledge in the spread of the disease, but poor understanding of HIV progression and oral manifestations of the disease.⁵

Almost 37% of participants in this study believed that the rapid HIV testing method was not as accurate as the ELISA and Western Blot methods. In contrast, a study by Moodley et al. demonstrated that the reliability of the HIV rapid tests could be compared with their corresponding ELISA results.¹⁷ Moodley et al. and Siegel et al. further postulated that the reliability of the rapid HIV tests is of a high caliber and that these tests are aligned with the standards set by the World Health Organization (WHO).^{17,18}

Table 1. Relationship between biographical data and option to implement HIV testing in the dental workplace.

Biographical data		Number of participants	Would you implement HIV testing in your dental workplace?				P-value
			Yes		No		
Gender	Male	54	32	(59.3%)	22	(40.7)	0.142
	Female	46	34	(73.9%)	12	(26.1%)	
Age group	23-28 years	24	17	(70.8%)	7	(29.2%)	0.965
	29-34 years	27	17	(63.0%)	10	(37.0%)	
	35-40 years	18	12	(66.7%)	6	(33.3%)	
	41> years	31	20	(64.5%)	11	(35.5%)	
Profession	Dental therapist	22	18	(81.8%)	4	(18.2%)	0.053
	Dental surgeon	69	43	(62.3%)	26	(37.7%)	
	Oral hygienist	7	5	(71.4%)	2	(28.6%)	
	Dental specialist	2	0	(0.0%)	2	(100.0%)	
Place of work	Private Dental practice	57	31	(54.4%)	26	(45.6%)	0.032
	Dental department in public hospital	34	27	(79.4%)	7	(20.6%)	
	Dental department in public clinic	6	5	(83.3%)	1	(16.7%)	
	Other (Mobile clinics)	3	3	(100.0%)	0	(0.0%)	
Years of experience	1-5 years	28	20	(71.4%)	8	(28.6%)	0.363
	6-10 years	24	13	(54.2%)	11	(45.8%)	
	11-15 years	15	12	(80.0%)	3	(20.0%)	
	>15 years	33	21	(63.6%)	12	(36.4%)	
Number of patients seen on weekly basis	<50	38	24	(63.2%)	14	(36.8%)	0.516
	50-100	41	26	(63.4%)	15	(36.6%)	
	101-150	12	8	(66.7%)	4	(33.3%)	
	>150	9	8	(88.9%)	1	(11.1%)	

Table 2. Knowledge of rapid HIV testing.

Questions	Total participants	Knowledge			P-value
		Yes	No	Unsure	
Cheaper than the conventional testing?	100	81.0%	9.0%	10.0%	0.000
Quicker than the conventional testing?	100	92.0%	3.0%	5.0%	0.000
Less invasive?	100	74.0%	12.0%	14.0%	0.000
Useful in areas with minimal infrastructure?	100	84.0%	7.0%	9.0%	0.000
As accurate as ELISA and Western blot?	100	22.0%	37.0%	41.0%	0.000

Table 3. Participants' positive perceptions on routine HIV testing at the dental.

Early detection and effective management of HIV (n=13; 28.9%)	Awareness and knowledge of HIV status (n=10; 24.4%)	Decreasing occupational risk (n=3; 7%)
1. Early diagnosis could assist with improving HIV/AIDS awareness. HIV testing offered at the dental workplace could increase access to communities that may not be seen timely by medical staff due to busy clinics and limited resources.	1. Routine HIV testing should be as important as checking for blood pressure and blood glucose levels.	1. Due to exposure to potential contaminations and high number of HIV positive patients, testing is prudent as staff are always aware of risk, even with the use of personal protective equipment.
2. HIV testing in the dental workplace is useful for the patient's welfare. The broadest spectrum of facilities should offer testing.	2. A large number of patients access dental services only and many of them do not know their status, so knowledge is key.	2. There are times where oral health care workers do get injuries and are so busy at work that they neglect to test themselves. Therefore HIV testing at the dental workplace is vital.
3. Patients can be counselled at the earliest and treatment can commence promptly.	3. Any means to increase awareness and HIV testing is good. Dentists can also be exposed to blood, so knowing a patient's status is important.	3. HIV testing at the dental workplace is integral, as we, health care workers, are always at risk of contracting HIV/AIDS.
4. Patients will know their status and how to look after themselves better.	4. HIV is a major problem. Patients can get tested quicker and know their status, thereby reducing the negative impact on the country.	

Thus rapid HIV tests could be a quick and cost effective method of testing for HIV.^{17,18} The authors however also highlighted the need for ongoing training, monitoring, and review of rapid HIV testing methods.^{17,18,19}

Department of Health outlined requirements for provider-initiated counselling and testing (PICT) services in all healthcare facilities.²¹ This could also be extended to the dental workplace.

According to WHO, "scaling up VCT is a public health and human rights imperative and must be linked to extensive efforts to achieve universal access to comprehensive HIV prevention, treatment, care and support".^{20:p.4} In line with WHO's recommendation, the South African

This is further supported by Bassett et al. who reported that routine voluntary HIV testing was able to identify nearly five times as many new cases per week.²² Hence, early diagnosis of HIV is essential for the improvement of treatment outcomes.²³ Vulnerable groups including chil-

dren should not be excluded in the HIV screening and testing strategies. According to Mohamed et al., a high prevalence of dental caries (78.8%) and an unmet treatment need of 90.4% were recorded among children with HIV/AIDS that visited the dental clinic in the Western Cape.²⁴ This again highlights the role that oral health care workers can play in HIV detection. Therefore, health planning in the district should include opportunities for oral health care to be integrated into HIV education and clinical management such as early diagnosis of HIV.⁴ These initiatives could contribute to strengthening the health system's response to HIV infections in the district and in the province.

The majority of participants (66%) indicated willingness to implement HIV counselling and testing in their dental workplace. This study finding is consistent with many international studies.^{13,25,26,27} An Australian study showed that the majority of dentists surveyed, supported rapid HIV testing in the dental workplace, with a large number of dentists advocating for immediate availability of rapid HIV testing.²⁵

Similarly, a study by Abe, Kolude and Adeyemi, suggested that Nigerian dentists acknowledged the dental workplace as being an extended platform for HIV testing and were optimistic about incorporating HIV testing into the dental setting, as well as expressed their willingness to undergo training for HIV testing.¹³ Pollack et al. found that dentists supported the importance of annual HIV testing for high risk individuals and expressed willingness to perform screening and testing for HIV.²⁶ Hutchinson et al. reported that rapid HIV testing was advocated when this service was within the scope of the dental practitioners' training.²⁷

The present study indicated that the majority of participants (76%) were comfortable treating a suspected HIV positive patient and 81% of the participants did not feel at risk for contracting the disease. Conversely, an Indian study found that only 60.7% of dentist participants were willing to treat HIV positive patients and 70.4% of the participants reported to be placed at an increased personal risk when treating suspected HIV positive patients.²⁸

One possible reason for this reported difference could be the inherent practitioner attitudes and beliefs around HIV. Additionally, strategies such as the National Strategic Plan 2017-2022 and UNAIDS 90-90-90 could play a role in increasing practitioner and public awareness of HIV.^{29,30} More research is required in this area to fully understand how practitioner beliefs and attitudes could influence their perceptions of risks related to HIV.

While the majority of participants in this study recognized the benefits of opportunistic HIV testing in the dental workplace, some barriers were also reported. These included: lack of appropriate training and skills in HIV counselling and testing and no clear guidelines on remuneration and support from the KwaZulu-Natal Department of Health. These findings are similar to other studies that reported oral health care workers from the private dental sector were less likely to implement HIV testing in the dental workplace due to lack of counselling skills, resources, time constraints and perceptions

that these services were not relevant within the scope of dentistry.^{31,32} A study by Siegel et al. suggested that dental practitioners were less likely to implement HIV testing in the dental setting due to the following reasons: liability for incorrect results, offending or upsetting patients, HIV testing as a procedure not within the dental scope, low acceptance of HIV testing in dental workplace, potential negative impact on the private dental practice, inadequate reimbursement, cost and time.¹⁸ Abe et al. added that lack of interest in HIV testing in the dental workplace was possibly linked to poor understanding of rationale behind rapid HIV testing, lack of insurance coverage (medical aid), and further cautioned that policy statements should come from governing authorities and not oral health care workers.¹³

Overall, this study indicated that oral health care workers' knowledge and training regarding HIV testing were inadequate. There was very little evidence to suggest that oral health workers actually provided HIV testing in the dental workplace. However, oral health care workers' attitudes and perceptions towards implementing HIV testing to the dental workplace was one of optimism and willingness. A suggestion to improve HIV testing in dental settings in eThekweni district could include the development of an oral health HIV testing policy to guide such services in both the public and private dental sectors. However such policy development should involve all stakeholders to ensure inclusiveness in decision making and practitioner buy-in.

Oral health policy and planning in the district and province could glean from best practices in HIV counselling and testing services in other countries and adapt these to local settings.⁸ From an educational perspective, training on HIV testing and counselling could be incorporated into the undergraduate dental curricula so as to better prepare dental graduates. Similarly refresher courses on voluntary HIV testing and counselling could be offered as part of continuing professional development for practitioners. In this way, patients could have increased accessibility to HIV testing and counselling with appropriate referral pathways for management and care. Simultaneously, oral health care workers could play more meaningful roles in addressing the HIV pandemic.

Study limitations

The study provided valuable insight into oral health care workers' knowledge, attitudes and practice of HIV testing, but some limitations were noted. The study focused exclusively on oral health care workers in the eThekweni district thus the generalizability of the study findings are limited. More research is required on a larger scale (national level) to further explore oral health care workers' knowledge, attitudes, perceptions towards HIV testing and counselling. It would be important to understand the interplay between oral health care workers' HIV knowledge and training and social and cultural norms that influence oral health care workers' attitudes and perceptions towards HIV testing. Over-reporting could have also been present with regards to oral health care workers' HIV testing practices. This observation is consistent with findings by Singh and Pottapinjara, and Ahamed et al. who also suggested that self-reported data could be over or under-reported in an effort to conform to social desirability.^{33,34}

CONCLUSION

The results indicated that oral health care workers' HIV testing knowledge and practice of HIV testing is sub-optimal. The majority of participants indicated not having training or skills in pre- and post-test HIV counselling and testing, but were generally optimistic towards offering HIV testing and counselling in the dental workplace. More guidance and direction are required from the KwaZulu-Natal Department of Health to operationalize such services.

Acknowledgement

Dr NR Maharaj, (Department of Health) for his guidance and input.

References

- UNAIDS. HIV and AIDS in South Africa. Avert Organization. 2019 [cited 16 September 2020]. Available from: <https://www.avert.org/professionals/hiv-around-world/sub-saharan-africa/south-africa>.
- Low M, MacDonell S. Graphs that tell the story of HIV in South Africa's provinces. Spotlight. 2019 [cited 16 September 2020]. Available from: <https://www.spotlightnsp.co.za/2019/08/05/graphs-that-tell-the-story-of-hiv-in-south-africas-provinces/>.
- National Department of Health of South Africa. National HIV Testing Services Policy: 2016. 2015; 23.
- Campo J, Cano J, del Romero J, et al. Role of the dental surgeon in the early detection of adults with underlying HIV infection/AIDS. *Med Oral Patol Oral Cir Bucal*. 2012; 17(3).
- Galane M. Knowledge, attitude and practices regarding HIV/AIDS among dental students at Medunsa oral health centre. University of Limpopo; 2012.
- Coogan MM, Greenspan J, Challacombe SJ. Oral lesions in infection with human immunodeficiency virus. *World Health Organization Bulletin*. 2005; 83(9): 700-6.
- Berberi A, Aoun G. Oral lesions associated with human immunodeficiency virus in 75 adult patients: a clinical study. *Journal of the Korean Association Oral Maxillofacial Surgeons*. 2017; 43(6): 388.
- Bradley ELP, Vidot DC, Gaul Z, Sutton MY, Pereyra M. Acceptability of oral rapid HIV testing at dental clinics in communities with high HIV prevalence in South Florida. *PLoS One*. 2018. Available from: <https://doi.org/10.1371/journal.pone.0196323>.
- Austin C. Rapid HIV Testing in the Dental Office. *DentistryQ*. 2009. Available from: http://cdeworld.com/courses/20185-Rapid_HIV_Testing_in_the_Dental_Office.
- Santella A, Conway DI, Watt RG. The potential role of dentists in HIV screening. *British Dental Journal*. 2016; 220(5): 229-33.
- Bhayat A, Yengopal V, Rudolph M. Predictive value of group I oral lesions for HIV infection. *Oral Surgery, Oral Medicine, Oral Pathology, Oral Radiology and Endodontology*. 2010; 109(5): 720-3.
- Agbelusi GA, Eweka OM, Umezudike KA, Okoh M. Oral manifestations of HIV. *IntechOpen*. 2013. doi: 10.5772/52941.
- Abe E, Kolude B, Adeyemi B. HIV testing in dental practice: perception and attitude of dentists in Southwestern Nigeria. *African Journal of Medicine and Medicinal Science*. 2014; 43(1): 201-8.
- Parish CL, Siegel K, Liguori T et al. HIV testing in the dental setting: perspectives and practices of experienced dental professionals. *AIDS Care*. 2017; 30(3): 347-52.
- Gumede S. Knowledge, Attitudes and Perceptions of Health Care Users Towards HIV Self-Testing At Selected Gateway Clinics At eThekweni District, Kwazulu-Natal. *AIDS Research and Treatment*. 2017; 15(1):103-9.
- Ramphoma KJ, Naidoo S. Knowledge, attitudes and practices of oral health care workers in Lesotho regarding the management of patients with oral manifestations of HIV/AIDS. *SADJ*. 2014; 69(10):446,448-53.
- Moodley D, Moodley P, Ndabandaba T, Esterhuizen T. Reliability of HIV rapid tests is user dependent. *South African Medical Journal*. 2008; 98(9): 707-11.
- Siegel K, Abel SN, Pereyra M, et al. Rapid HIV testing in dental practices. *Am J Public Health*. 2012; 102(4): 625-32.
- Mwisongo A, Peltzer K, Mohlabane N, Tutshana B. The quality of rapid HIV testing in South Africa: An assessment of testers' compliance. *African Health Sciences*. 2016; 16 (3): 646-54.
- WHO. Scaling up HIV testing and counselling in the WHO European Region as an essential component of efforts to achieve universal access to HIV prevention, treatment, care and support policy framework. 2010: 4.
- Hansoti B, Hill SE, Whalen M, et al.. Patient and provider attitudes to emergency department-based HIV counselling and testing in South Africa. *South African Journal of HIV medicine*. 2017; 18(1).
- Bassett IV, Giddy J, Nkera J, et al. Routine Voluntary HIV Testing in Durban, South Africa: The experience from an outpatient department. *Journal of acquired immune deficiency syndromes*. 2007; 46(2): 181-6.
- Dimba EAO, Yengopal V, Joshua E, Thavarajah R, Balasundaram S. Access and management of HIV-related diseases in resource-constrained settings: a workshop report. *Oral Diseases*. Wiley Online Library. 2016; 22 (S1):206-210.
- Mohamed N, Mathiba OP, Mulder R. Oral status of HIV-infected children aged 12 years or younger who attended a Paediatric Infectious Diseases Clinic in Cape Town. *Clinical and Experimental Dental Research*. 2019; 6(1): 75-81.
- Santella AJ, Schlub TE, Schifter M, Tolani M, Hillman RJ. Australian dentists' perspectives on rapid HIV testing. *Australian Dental Journal*. 2015; 61(3).
- Pollack HA, Pereyra M, Parish CL, et al. Dentists' Willingness to Provide Expanded HIV Screening in Oral Health Care Settings: Results From a Nationally Representative Survey. *American Journal of Public Health*. 2014; 104(5): 872-80.
- Hutchinson MK, van Devanter N, Phelan J, et al. Feasibility of implementing rapid oral fluid HIV testing in an urban University Dental Clinic: a qualitative study. *BMC Oral Health*. 2012; 12(1).
- Dhanya RS, Hegde V, Anila S, et al. Knowledge, Attitude, and Practice towards HIV Patients among Dentists. *J Int Soc Prev Community Dent*. 2017; 7(2):148-53.
- South African National Aids Council (SANAC). The National Strategic Plan (NSP) 2017- 2022. 2016.
- [cited 22 September 2020]. Available from: <http://nsp.sanac.org.za/>.
- UNAIDS. Ending Aids: Progress Towards the 90-90-90 Targets. Joint United Nations Programme on HIV/AIDS. 2017. [cited 22 September 2022] Available from: https://www.unaids.org/en/resources/documents/2017/20170720_Global_AIDS_update_2017.
- Patton L, Santos V, McKaig R, Shugars D. Education in HIV risk screening, counseling, testing, and referral: survey of U.S. dental schools. *Journal of Dental Education*. 2002; 66(10): 1169-77.
- Greenberg BL, Glick M, Julie FH, Kantor ML. Dentists' attitudes toward chairside screening for medical conditions. *Journal of the American Dental Association*. 2010; 141: 52-62.
- Singh S, Pottapinjara S. Dental undergraduate students' knowledge, attitudes and practices in oral health self-care: A survey from a South African university. *African Journal of Health Professional Education*. 2017; 9(2): 83-7.
- Ahamed S, Moyin S, Punathil S, et al. Evaluation of the oral health knowledge, attitude and behavior of the preclinical and clinical dental students. *Journal of International Oral Health*. 2015; 7(6): 65-70.



No.1 DENTIST RECOMMENDED BRAND FOR SENSITIVE TEETH

*GfK New expert performance tracking 2018.

For any product safety issues, please contact GSK on +27 11 745 6001 or 0800 118 27
Trademarks are own or licensed by the GSK group of companies.



With clinically proven **Dual** relief

TEETH*

4.

Orthodontic repositioning of traumatically intruded permanent incisors - A report of three cases

SADJ February 2021, Vol. 76 No. 1 p14 - p21

H Singh¹, M Mittal², P Sharma³, A Kumar⁴, P Kapoor⁵

ABSTRACT

Intrusive luxation of permanent teeth is one of the most serious traumatic dental injuries involving damage to the gingival tissue, periodontal ligament, cementum, bone and to the neurovascular supply of the pulp. In addition to disruption of normal tooth development and eruption, it can also lead to pulpal necrosis, root resorption and marginal bone loss. Based on the extent/severity, intrusion maybe classified into mild (<3mm), moderate (3-6mm) and severe (>6mm).

Available techniques for managing intrusive luxation include a wait-and-watch approach to allow for spontaneous re-eruption, orthodontic traction and surgical repositioning. The type of treatment approach employed depends upon the stage of root development, severity of intrusive luxation and the presence or absence of alveolar fractures.

It is difficult to predict reliable outcomes with these approaches, since the presence of variables such as the severity of intrusion, associated crown/root fracture, stage of root development and presence of alveolar fractures may alter the prognosis.

The present article presents a series of three cases with intrusive luxation of permanent incisors successfully treated using an interdisciplinary approach involving orthodontic traction along with endodontic rehabilitation.

Author affiliations:

1. **Harpreet Singh:** BDS, MDS, Associate Professor, Department of Orthodontics, ESIC Dental College, Rohini, Delhi, India.
2. **Meenu Mittal:** BDS, MDS, Professor, Department of Paediatric Dentistry, ESIC Dental College, Rohini, Delhi, India.
3. **Poonam Sharma:** BDS, MDS, Professor, Department of Orthodontics, ESIC Dental College, Rohini, Delhi, India.
4. **Ashok Kumar:** BDS, MDS, Associate Professor, Department of Paediatric Dentistry, ESIC Dental College, Rohini, Delhi, India.
5. **Pranav Kapoor:** BDS, MDS Professor, Department of Orthodontics, ESIC Dental College, Rohini, Delhi, India.

Corresponding author: Meenu Mittal

Professor, Department of Paediatric Dentistry, ESIC Dental College, Rohini, Delhi, India.

Email: meenu20feb@gmail.com

Author contributions:

1. **Harpreet Singh:** Principal researcher, data collection, writing article - 20%
2. **Meenu Mittal:** Principal researcher, data collection, writing article - 20%
3. **Poonam Sharma:** Principal researcher - 20%
4. **Ashok Kumar:** Writing article, advisor - 20%
5. **Pranav Kapoor:** Writing article, advisor - 20%

Keywords

Trauma, Intrusive luxation, orthodontic repositioning.

INTRODUCTION

Intrusive luxation of permanent teeth, comprising 0.3 to 2.0% of traumatic dental injuries in permanent dentition,¹ is a severe dental injury that may cause extensive damage to the tooth and periodontium leading to the disruption of pulpal blood supply, crushing of periodontal ligament (PDL) with stripping away of cementum & PDL, and trauma to the surrounding alveolar bone.

Intrusion may also result in a disruption in the normal tooth development and eruption, root resorption and marginal bone loss.²⁻⁵ According to the Royal College of Surgeons of England, intrusion can be classified into mild (<3mm), moderate (3-6mm) and severe (>6mm) types.⁶

Treatment modalities employed for intrusive luxation include: 1). Waitful watching for spontaneous re-eruption, 2). Surgical repositioning, or 3). Orthodontic repositioning. Since the contemporary literature has very few studies with a limited number of teeth involved, consensus regarding the outcome of the three treatment approaches is divided. Also, it is difficult to predict reliable outcomes with these treatment approaches since the presence of other variables such as severity of intrusion, associated crown/root fracture, stage of root development and presence of alveolar fracture may affect outcomes.⁷

There is a general agreement that intruded immature teeth should be allowed to erupt spontaneously.^{4,5,8} Variations in the recommended duration of waiting for spontaneous re-eruption exist in literature, with Al Badri et al.⁵ recommending 2 weeks, Stewart et al.⁸ 4 weeks and International Association of Dental Traumatology (IADT) guidelines⁹ recommending a few weeks.

Spontaneous re-eruption following injury is unpredictable and relying on it can be over optimistic.⁷ In case of severe intrusion, delayed repositioning leaves the root in close contact with the alveolar bone which facilitates replacement root resorption and ankylosis.^{10,11,12} Moreover, associated complications such as external root resorption and loss of marginal bone support may further complicate the treatment progress. Incidence of pulp necrosis and root resorption in 63% of the teeth with open apex and 100% of teeth with closed apex has been reported with spontaneous re-eruption.¹⁰

Surgical repositioning is useful as it releases peri-radicular compression areas and removes the bacteria contaminated crown surface from its position in the socket.⁴ However, this approach, at the same time, leaves the intruded tooth with insufficient supporting alveolar bone and PDL, thereby resulting in an unaesthetic outcome.¹⁰

On the other hand, orthodontic repositioning is a more biologically sound method of repositioning the tooth, though it may not be superior to surgical repositioning.^{2,4,13} It offers the advantage of causing less marginal bone loss and facilitates better gingival and periodontal healing. Orthodontic repositioning is suggested when no spontaneous re-eruption is observed within few weeks or when a mature tooth has been intruded 3-7mm or an immature tooth has been intruded more than 7mm.⁹

There is increasing evidence that orthodontic repositioning methods have improved outcomes,^{8,14} are more conservative, with a lower associated risk of ankylosis and other complications.¹⁰ Coronal migration of the periodontium occurs during slow orthodontic extrusion using light forces, as the tension of the periodontal fibers is delivered directly to the bone. Institution of orthodontic treatment also precludes the need for local anesthetic in an already fearful child.

If roots are fully formed or nearly so, root canal treatment is sought necessary in addition to both surgical and orthodontic repositioning.^{8,15}

The present case series demonstrates three cases of intrusive luxation of permanent incisors successfully managed by orthodontic repositioning, followed by endodontic therapy.

CASE REPORT

Case 1

A 9-year old boy reported to the Department of Paediatric Dentistry, ESIC Dental College, Delhi with an injury to the chin (Fig. 1). The patient gave a history of trauma to the chin following a fall from the stairs 2 weeks back. There was history of bleeding from oral cavity and difficulty in breathing.

Clinical examination revealed intrusion of 11, 12, 21 & 22 with anterior open bite, bunched up and painful gingival tissue in relation to 11 & 21 and obstruction of nasal airway because of encroachment of the nasal passage (Fig. 2).

The patient reported pain on percussion of the intruded upper right and left incisors. Radiographic examination including an IOPA X-ray and OPG revealed that the roots of the intruded teeth were more than 2/3rd formed with an immature apex (Fig. 3A-C). The 3-dimensional cone-beam computed tomography (CBCT) images confirmed that the dislocated 11 and 21 had penetrated the floor of the nasal cavity with resulting superior displacement of the fracture segment (Fig. 4). No associated crown or root fracture was observed. CBCT also revealed bilateral hypertrophy of inferior nasal turbinate and a right subcondylar fracture with medial displacement of fractured condylar head (Fig. 4).

It was decided to initiate orthodontic repositioning of the intruded teeth. Since the patient was in mixed dentition, a 2 x 4 appliance (0.022-inch x 0.028-inch slot MBT prescription) was placed in the maxillary arch. Alignment and leveling was initiated using superelastic 0.012-inch Nickel-Titanium (NiTi) arch wire for a period of 4 weeks (Fig. 5A). Repositioning of incisors continued with light orthodontic force (approx. 40g) applied with the help of an elastomeric thread tied to two helices on a stabilizing 0.016 x 0.022-inch SS arch wire, which in turn prevented any arch deformation due to reactionary forces (Fig. 5B). The following sequence of arch wires was used to level the arch: 0.018-inch NiTi wire, 0.016 x 0.022-inch SS wire, followed by 0.018 x 0.025-inch SS wire during stabilization phase (Fig. 5C)

After 7 months of active treatment, debonding was done and a Hawley's appliance was delivered to be used as a retainer for one year (Figs. 6, 7 & 8). The patient was satisfied with his clinical appearance at 4 years post injury follow up (Fig. 9A, B). However, the IOPA X-ray taken at 4 years follow-up revealed root resorption with narrowing of canals of 12 & 22 and periapical pathology in relation to 11 & 21 (Fig. 9C). Endodontic treatment was then performed in 11, 12, 21 & 22 (Fig. 9D).

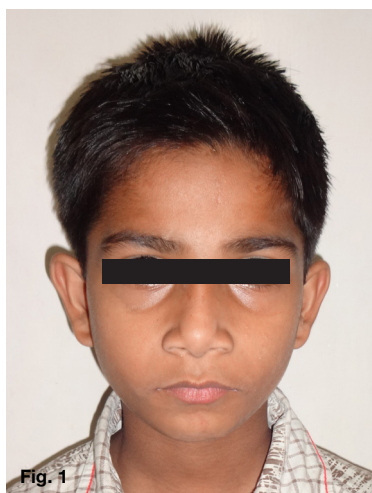

Figure 1. Case 1 - Pretreatment frontal photograph.

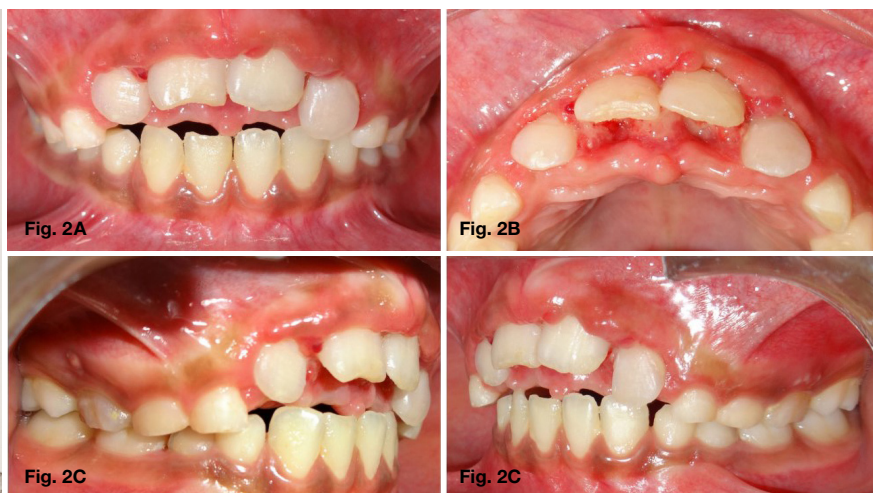

Figure 2. Case 1 - Pretreatment intraoral photographs showing traumatic intrusion of 11, 12, 21 & 22 with anterior open bite.

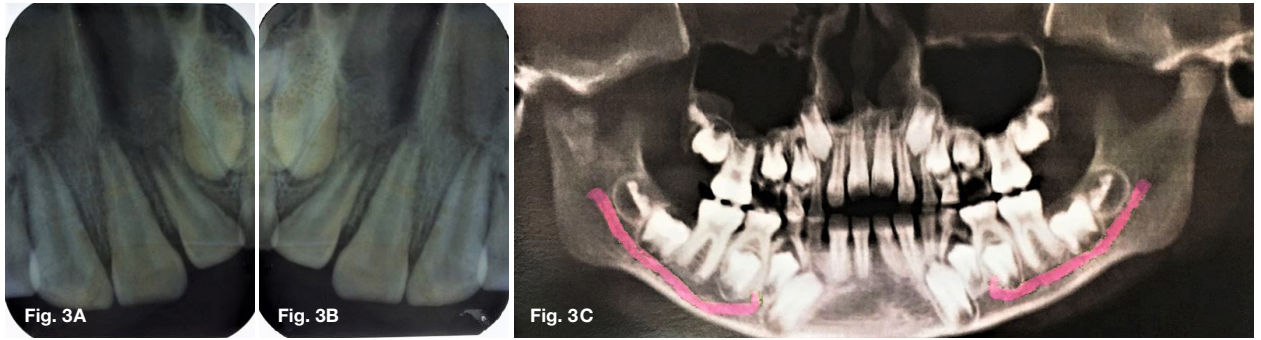


Figure 3. Case 1 - Pretreatment radiographs: A. IOPA of left central and lateral incisors. B. IOPA of right central and lateral incisors. C. OPG.

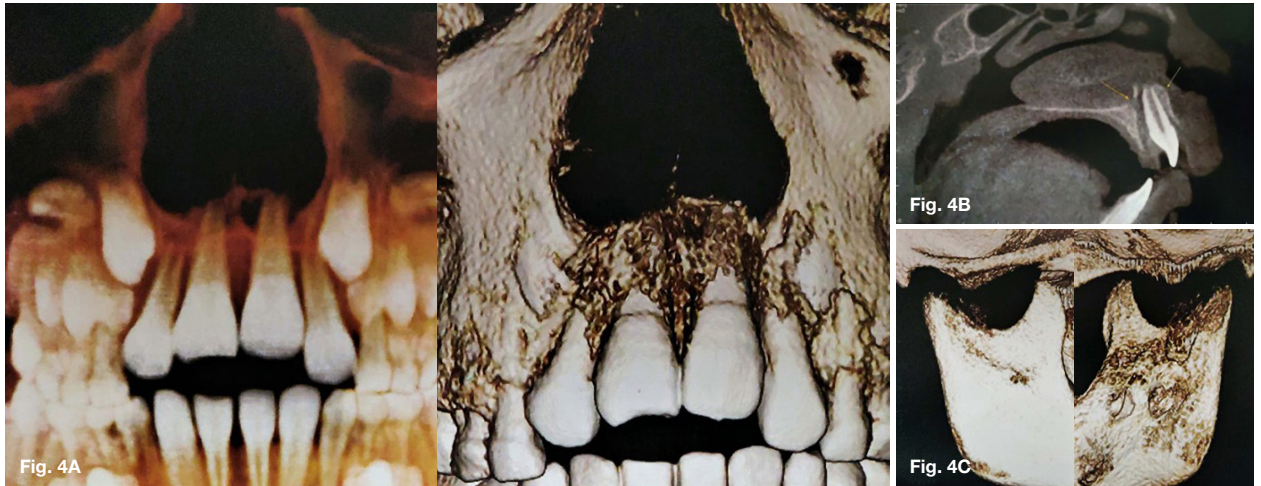

Figure 4. Case 1 - Pretreatment CBCT scan showing intrusion in nasal cavity and right subcondylar fracture.

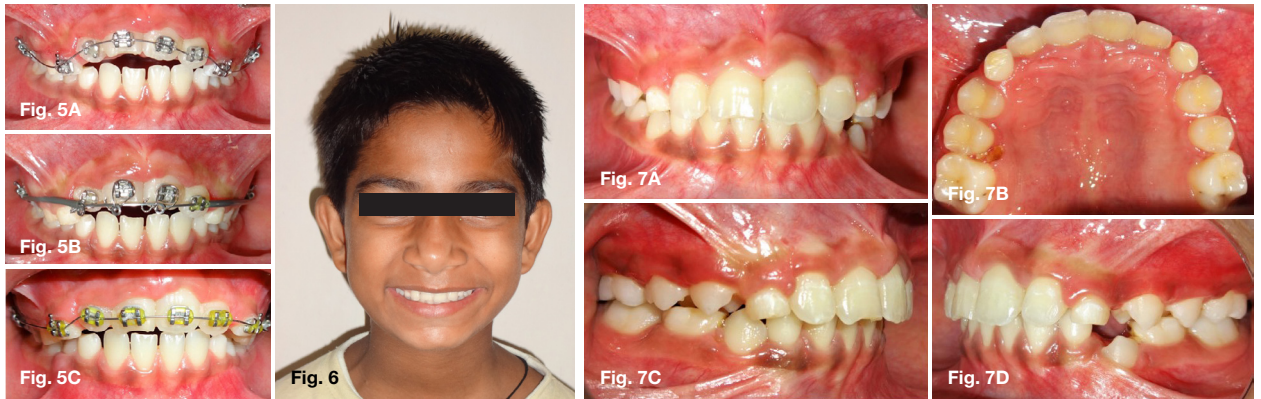


Figure 5. Case 1 - Treatment progress photographs: A. Alignment using 0.012" NiTi wire. B. Progression of incisors repositioning. C. Leveling in progress.

Figure 6. Case 1 - Post treatment photograph depicting good smile esthetics.

Figure 7. Case 1 - Post-treatment intraoral photographs showing well-aligned incisors.

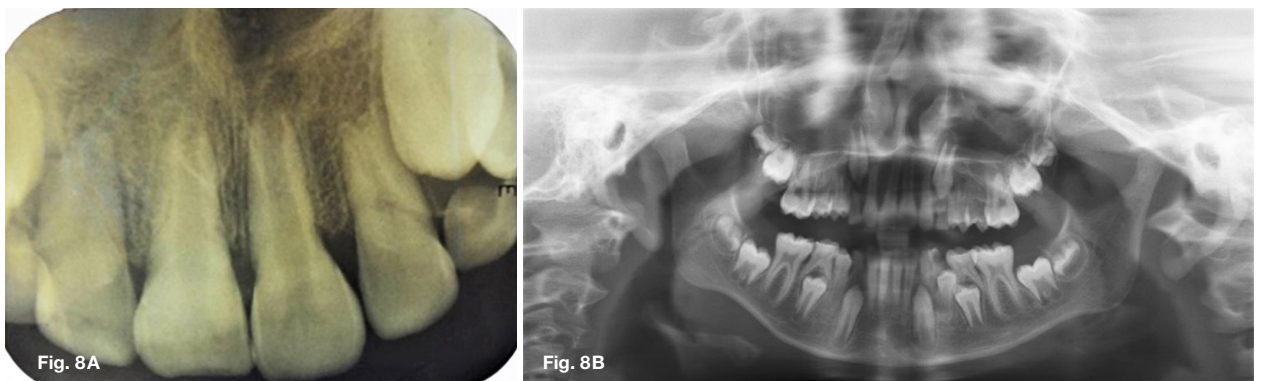


Figure 8. Case 1 - Post treatment radiographs: A. IOPA. B. OPG.

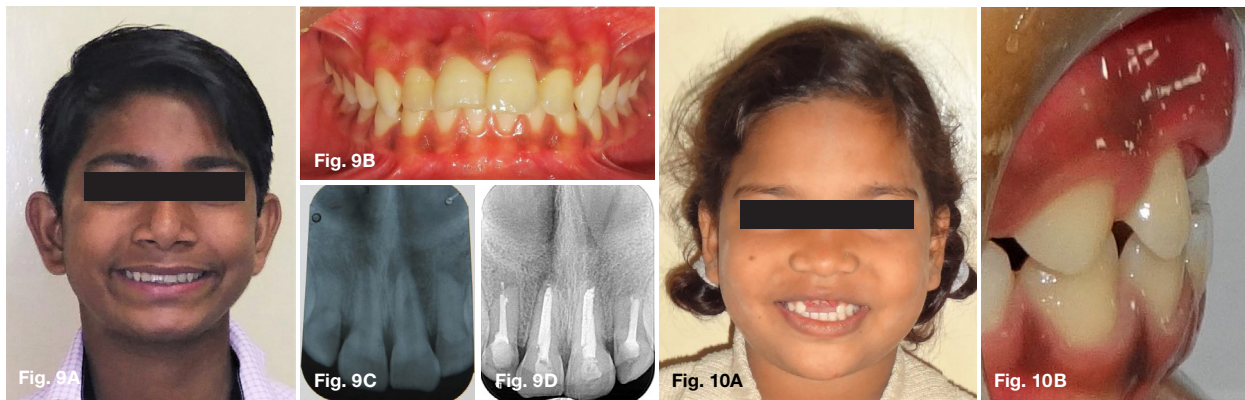


Figure 9. Case 1 - Four year follow up photographs: A. Frontal smile view. B. Intraoral frontal view. C. IOPA pre-endodontic treatment. D. IOPA post endodontic treatment.

Figure 10. Case 2 - Pretreatment posed smile and intraoral anterolateral view.

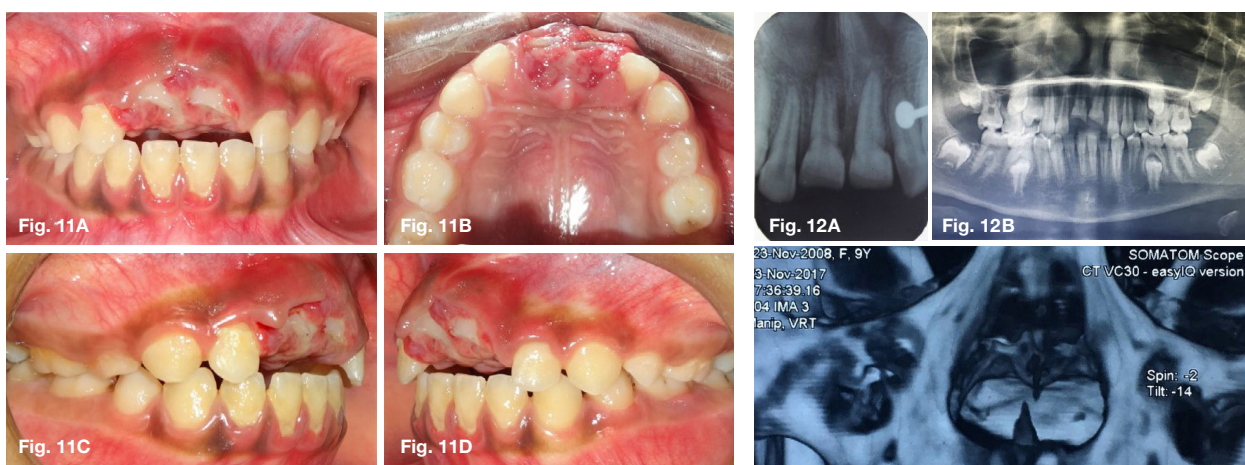


Figure 11. Case 2 - Pre-treatment intraoral photographs showing traumatic intrusion of 11 & 21.

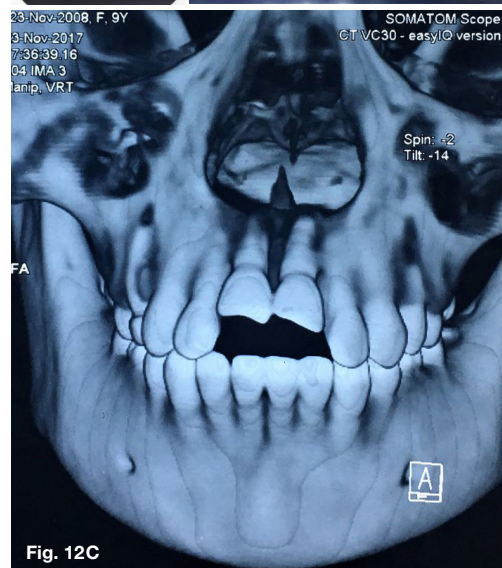


Figure 12. Case 2 - Pre-treatment radiographs: A. IOPA. B. OPG. C. Spiral NCCT showing intrusion of incisors into the floor of nasal cavity.

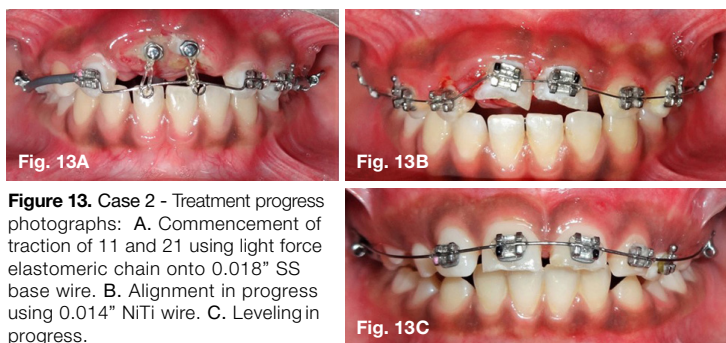


Figure 13. Case 2 - Treatment progress photographs: A. Commencement of traction of 11 and 21 using light force elastomeric chain onto 0.018" SS base wire. B. Alignment in progress using 0.014" NiTi wire. C. Leveling in progress.

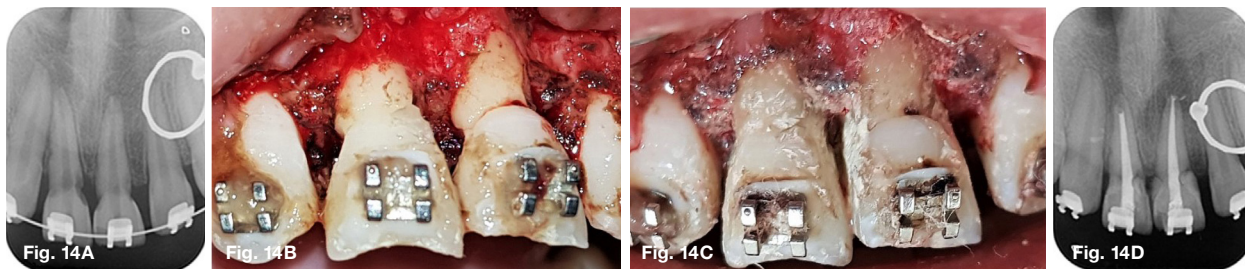


Figure 14. Case 2 - Intraoperative radiographs and photographs: A. IOPA showing resorption areas on mesial and distal surfaces of 11 & 21. B. Resorption defects seen on mesial and distal surfaces of 11 & 21. C. Restoration of defects with biodentine. D. IOPA with biodentine and metapex.

Case 2

A 9 year old female reported to the Department of Paediatric Dentistry, ESIC Dental College, Delhi with the chief complaint of pain in her upper front teeth (Fig. 10). The patient gave history of fall from bed 2 weeks back resulting in a fracture of her upper front teeth. She complained of persistent headache post injury. Bleeding from oral cavity was reported at the time of trauma which stopped following the application of a pressure pack at a private clinic. Clinical examination revealed inflamed gingiva with respect to 11 & 21, while in other areas of oral cavity the gingiva was pale pink in color (Fig. 10, 11).

Traumatic intrusion and Ellis class II fracture was observed in the maxillary left and right central incisors. IOPA X-ray and OPG revealed fully mature roots of 11 & 21 (Fig. 12A, B). Spiral non-contrast CT scan (Spiral NCCT) confirmed the perforation of nasal floor by the intruded incisors (Fig. 12C).

Orthodontic treatment was initiated using a gingival retraction cord to gain access for bonding lingual buttons on the labial aspects of 11 & 21. An 0.018-inch SS wire with 2 helices was used for gradual traction of 11 & 21 using light force elastomeric chain (Fig. 13A). Two weeks later, once the labial surface of the intruded incisors was sufficiently visible, MBT brackets were bonded on 11 & 21 and an improved superelastic 0.014-inch NiTi arch wire was ligated (Fig. 13B).

Root canal treatment was planned for the next sitting. The patient, however, missed an appointment, and when she reported 2 months later, the arch was nearly leveled (Fig. 13C). The IOPA X-ray revealed small areas of external resorption in the cervical area of crown and roots of 11 & 21 (Fig. 14A).

Root canal access was gained in 11 & 21, and calcium hydroxide paste (Metapex; Meta Biomed Ltd, Cheongju, Chungbuk, Korea) was placed in the canals. It was decided to restore the cervical resorption areas and a mucoperiosteal flap was raised and granulation tissue was removed from cervical areas of these teeth (Fig. 14B).

Biodentine was used for restoration of the cervical defects (Fig. 14C). An 0.016 x 0.022-inch SS wire was used during the stabilization phase, during which endodontic treatment was completed (Fig. 14D). After 8 months of active treatment, the arch was debonded and a Hawley's retainer was delivered (Fig. 15). Clinical outcome was stable and no further resorption was seen at 2 years follow-up (Fig. 16).

Case 3

A 10-year old boy reported with history of trauma from a classroom bench in school one week back (Fig. 17). On clinical examination, 22 & 23 were found to be intruded with 22 showing severe intrusion (>7mm) (Fig. 18).

OPG confirmed intrusion and revealed a partially immature root apex of 22 and wide-open root apex of 23 (Fig. 19). It was decided to commence orthodontic traction to correct intrusion after waiting for one more week.

A lingual button was bonded on to the palatal aspect e of 22 as adequate space was not available on the labial surface. A base arch wire of 0.017 x 0.025-inch SS was used with ligated overlay wire of 0.014-inch NiTi (Fig. 20A). Once 22 had been sufficiently extruded, an MBT bracket was also bonded on 22.

Further alignment and leveling progressed with 0.016-inch NiTi wire, 0.016 x 0.022-inch NiTi wire and finally with an 0.018 x 0.025-inch SS wire (Fig. 20B). Similarly, bonding was done in the lower arch and a normal progression of continuous arch wires was used to level, align, and coordinate the arches.

During the course of orthodontic traction, apical root resorption was observed in 22 (Fig. 20C). Endodontic access was gained in 22 and metapex was placed in the canal (Fig. 20D, 21A). Once continuous lamina dura was discernable, the canal was obturated with gutta-percha (Fig. 21B, C). Four years follow-up shows no further root resorption along with good occlusion & aesthetics (Fig. 22).

DISCUSSION

In spite of being widely and more closely studied as compared to other injuries, intrusive luxation often poses a management and prognostic challenge to the clinician as, till date, there is lack of consensus on how to best treat an intrusive injury. Various factors that govern the prognosis of intrusive luxation include: the extent of root development, patient's age, degree (severity) of intrusion, tooth type, presence of gingival laceration, number of intruded teeth and associated crown/root fractures.

Root fractures may be infrequently associated with intrusion, with the documented incidence of about 1.4%.¹⁶ Presence of an associated root fracture tends to necessitate additional management such as reduction of the coronal fragment and rigid splinting for a period of 3 months; and/or intra-radicular splints in the form of metal pins in cases of pulp necrosis.¹⁷ Of all the factors affecting prognosis, severity of intrusion is considered to be the most critical.^{7,18,19} Intrusions up to 3 mm have been shown to have excellent prognosis, whereas intrusions > than 6mm have poor prognosis with greater chances of pulp necrosis and inflammatory root resorption.

Utilization of CT/ CBCT scans with 3-dimensional reformations in such cases aids in exact localization and visualization of the intrusive injury, particularly root fractures, lateral luxation, nasal floor perforation and any associated complications affecting the temporomandibular joint.

In case 1, severe traumatic intrusion (both central incisors intruded >5mm) with the involvement of multiple teeth was observed. Since the patient reported two weeks after the injury along with an associated complaint of difficulty in breathing, orthodontic repositioning was commenced immediately.

Hence the possibility of formation of a bony bridge of ankylosis following trauma¹¹ was avoided and good periodontal healing with adequate bone support was achieved.

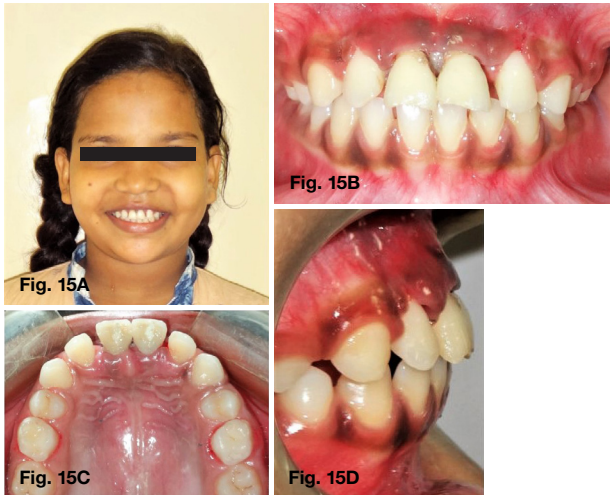

Figure 15. Case 2 - Post-treatment posed smile and intraoral photographs.

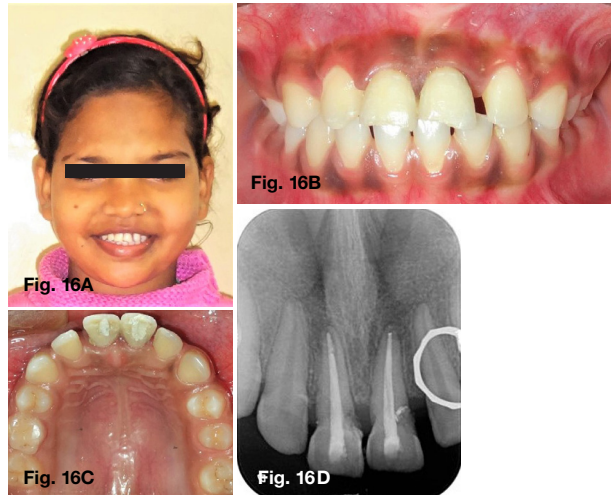

Figure 16. Case 2 - Two year follow up photographs showing stability of achieved results.

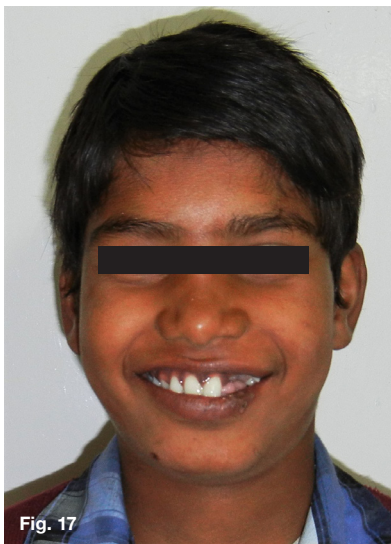

Figure 17. Case 3 - Pretreatment posed smile photograph.

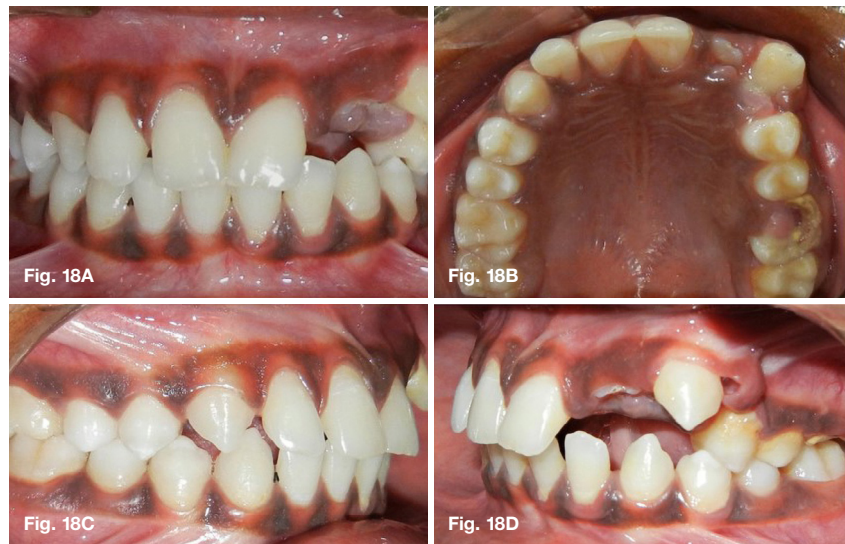

Figure 18. Case 3 - Pretreatment intraoral photographs showing intruded lateral incisor and labially displaced canine.

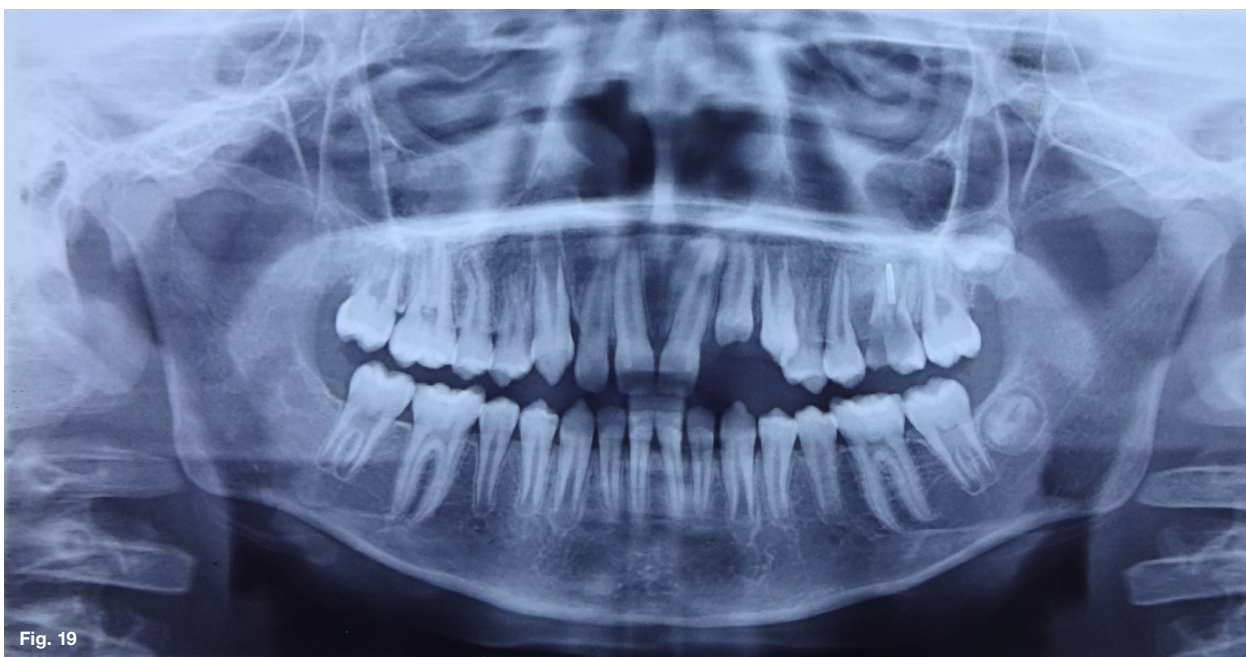

Figure 19. Case 3 - Pretreatment OPG.

In **Case 2**, since both the incisors had mature apices, and the extent of intrusion was about 5 mm, treatment was started immediately in accordance with the IADT guidelines.⁹

These two cases demonstrating complete penetration into the nasal cavity (**Case 1 & 2**) were thus treated with orthodontic extrusion and good results were obtained.

In **Case 3**, demonstrating immature apices in 22 and 23, orthodontic extrusion was initiated after waiting for one more week⁹ and continued root formation was observed during the course of orthodontic treatment. However, some apical root resorption was observed in 22 which can be attributed to the higher severity of intrusion (>7mm) as compared to 23. As was also observed in **Case 1**, a severe degree of intrusion may be the cause of root resorption.

Root resorption tends to occur more frequently in teeth with more complete root development.^{1,20} In **Case 2**, during the course of orthodontic traction, some resorption defects were observed in cervical region of crown and root, which may have developed as a result of damage to the periodontal ligament, orthodontic forces or the severe injury itself.

Endodontic considerations

Disruption of pulpal blood supply is a major concern in intruded teeth which can lead to pulp necrosis unless revascularization takes place. A strong association has been reported between the width of apical foramen and the chance of revascularization.^{1,21} Hence no endodontic treatment was performed in case 1 & 3. However, once root resorption was observed in 22 of **Case 3** and root resorption with periapical pathology in **Case 1**, the endodontic treatment was initiated, and further root resorption avoided. Root canal therapy using a temporary filling with calcium hydroxide is recommended⁹ because of its ability to arrest the ongoing resorption process.²²

In teeth with mature apices, the higher incidence of pulp necrosis following intrusion necessitates earlier removal of pulp to prevent infection and inflammatory root resorption.⁸ Thus endodontic treatment was planned in **Case 2** as soon as the access could be gained, but the patient missed an appointment and treatment was thus delayed.

The ideal time of maintenance of calcium hydroxide dressing in the canal is not established in literature. It can be applied for a long term (upto 6 months) to ensure periodontal health prior to final root canal filling.²² Ebeleseder et al.²⁰ support a period of 6-9 months while de Alencar et al.¹⁸ suggest its maintenance till PDL is re-established and intact lamina dura is seen. Calcium hydroxide should be changed periodically.¹⁸ Once radiographically intact lamina dura was observed in present cases, teeth were obturated with gutta percha.

Orthodontic considerations

Orthodontic management of intruded teeth using extremely light forces, as performed in above cases, facilitates more biological repositioning as compared to surgical re-

positioning. Use of self-etch primer instead of the traditional method of acid etch, wash and bonding, reduces the necessary steps and time required for bonding, thereby making it easier to maintain a blood free zone for placement of brackets.

Self-ligating brackets may be an alternative option as these brackets can be opened or closed gently without creating additional stresses on the teeth, thus reducing the patient's discomfort. In addition, use of improved superelastic NiTi wires provide light consistent forces and allows easy displacement into brackets.²³ During alignment of severely intruded teeth, placement of super-elastic NiTi wire piggyback over a rigid rectangular stainless-steel base wire helps prevent any arch deformation due to reactionary forces. More so, adherence to simple biomechanical principles is crucial for securing acceptable treatment outcomes.

CONCLUSION

Interdisciplinary approach involving a combination of appropriate orthodontic mechanics and endodontic treatment helped achieve clinically esthetic and functionally acceptable outcomes in the above-mentioned cases. The guidelines available in literature should be followed but with the provision to individualize the treatment plan as per the requirement of each particular case.

Conflict of interest

There is no conflict of interest.

References

1. Andreasen JO, Bakland LK, Andreasen FM. Traumatic intrusion of permanent teeth. Part 2. A clinical study of the effect of preinjury and injury factors, such as sex, age, stage of root development, tooth location, and extent of injury including number of intruded teeth on 140 intruded permanent teeth. *Dent Traumatol.* 2006; 22: 90-8.
2. Omar S, Freccia WF, Retamozo B, Bakland LK. Traumatically intruded permanent teeth: Three case reports and a review of current recommendations. *J Calif Dent Assoc.* 2017; 45(5): 235-43.
3. Carvalho V, Jacomo DR, Campos V. Frequency of intrusive luxation in deciduous teeth and its effects. *Dent Traumatol* 2010; 26(4): 304-7.
4. Andreasen JO, Bakland LK, Andreasen FM. Traumatic intrusion of permanent teeth. Part 3. A clinical study of the effect of treatment variables such as treatment delay, method of repositioning, type of splint, length of splinting and antibiotics on 140 teeth. *Dent Traumatol.* 2006; 22: 99-111.
5. Al-Badri S, Kinirons M, Cole BOI, Welbury RR. Factors affecting resorption in traumatically intruded permanent incisors in children. *Dent Traumatol.* 2002; 18: 73-6.
6. Kinirons MJ. Treatment of traumatically intruded permanent incisor teeth in children, UK National clinical guidelines in Pediatric Dentistry. *Int J Pediatr Dent.* 1998; 8: 165-8.
7. Humphrey JM, Kenny DJ, Barrett EJ. Clinical outcomes for permanent incisor luxations in a pediatric population. I Intrusions. *Dent Traumatol.* 2003; 19: 266-73.
8. Stewart C, Dawson M, Shafi I, Kinirons M, Welbury R. A study of the management of 55 traumatically intruded permanent incisor teeth in children. *Eur Archives Pediatr Dent.* 2009; 10(1): 25-8.

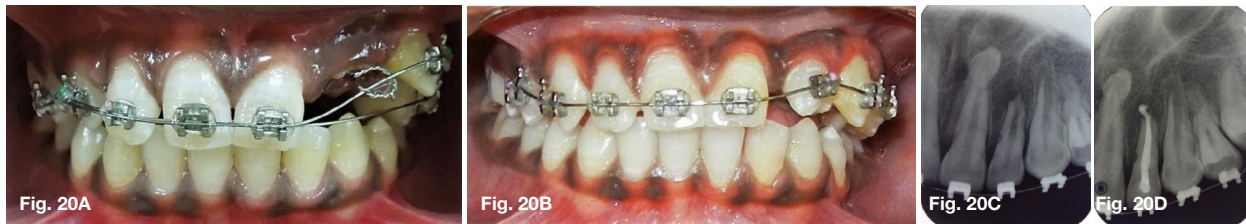

Figure 20. Case 3 - Mid treatment photographs: A. Traction of 22 and 23 using superelastic 0.014" Niti wire. B. Progression of alignment and leveling. C. IOPA showing root resorption in 22. D. IOPA with metapex obturation in 22.

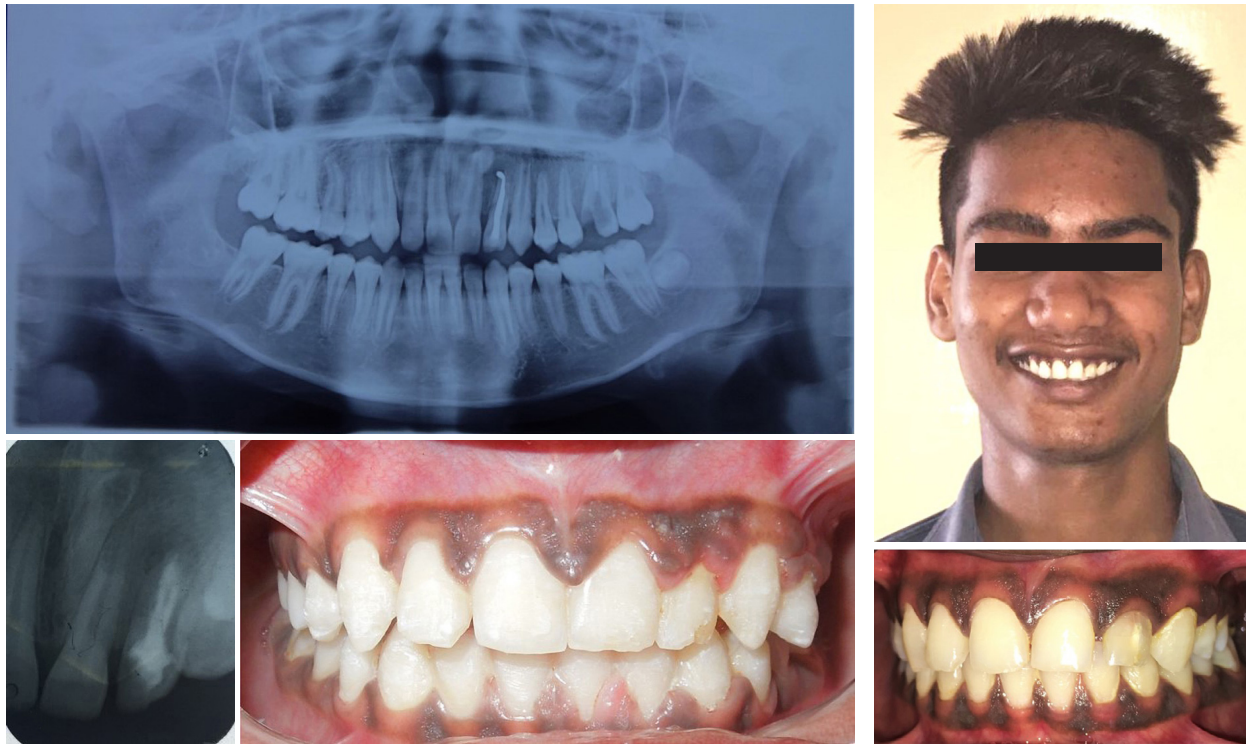

Figure 21. Case 3 - Immediate posttreatment radiographs and photograph: A. OPG. B. Post gutta-percha obturation IOPA. C. Intraoral frontal view.

Figure 22. Case 3-4 year follow-up depicting well-maintained stable results.

9. DiAngelis AJ, Andreasen JO, Ebeleseder KA, Kenny DJ, Trope M, Sigurdsson A, et al. International Association of Dental Traumatology guidelines for the management of traumatic dental injuries: 1. Fractures and luxations of permanent teeth. *Dent Traumatol.* 2012; 28: 2-12.
10. Calasans-Maia JA, Calasans-Maia MD, Matta ENR, Ruellas ACO. Orthodontic movement in traumatically intruded teeth: a case report. *Dent Traumatol.* 2003; 19: 292-5.
11. Turley PK, Crawford LB, Carrington KW. Traumatically intruded teeth. *Angle Orthod* 1987; 57(3): 234-44
12. Andreasen FM, Vestergaard PB. Prognosis of luxated permanent teeth- the development of pulp necrosis. *Endod Dent Traumatol.* 1985; 1: 205-20.
13. AlKhalifa JD, AlAzemi AA. Intrusive luxation of permanent teeth: A systemic review of factors important for treatment decision making. *Dent Traumatol.* 2014; 30: 169-75.
14. Chaushu S, Shapira J, Helling I, Becker A. Emergency orthodontic treatment after the traumatic intrusive luxation of maxillary incisors. *Am J Orthod Dentofacial Orthop.* 2004; 126(2): 162-72.
15. Andreasen FM, Zhijie Y, Thomson BL. Relationship between pulp dimension and development of pulp necrosis after luxation injuries in the permanent dentition. *Endod Dent Traumatol.* 1986; 2: 90-8.
16. Andreasen JO, Bakland LK, Matras RC, Andreasen FM. Traumatic intrusion of permanent teeth. Part 1. An epidemiological study of 216 intruded permanent teeth. *Dent Traumatol.* 2006; 22: 83-9.
17. Seddon RP. Concomitant intrusive luxation and root fracture of a central incisor - report of a case. *Endod Dent Traumatol.* 1997; 13: 99-102.
18. de Alencar AH, Lustosa-Pereira A, de Sousa HA, Figueiredo JH. Intrusive luxation a case report. *Dent Traumatol* 2007; 23: 307-12.
19. Chacko V, Pradhan M. Management of traumatically intruded young permanent tooth with 40-month follow-up. *Austr Dent J.* 2014; 59: 240-4.
20. Ebeleseder KA, Santier G, Glockner K, Hulla H, Pertl C, Quenhenberger F. An analysis of 58 traumatically intruded and surgically extruded permanent teeth. *Endod Dent Traumatol.* 2000; 16: 34-9.
21. Andreasen FM, Yu Z, Thomsen BI. The relationship between pulpal dimensions and the development pulp necrosis after luxation injuries in the permanent dentition. *Endod Dent Traumatol.* 1996; 2: 90-8.
22. Ingle JI, Bakland LK, Baumgartner JC. Endodontic considerations in dental trauma in Ingle's Endodontics, 6th Edition, BC Decker Inc, Hamilton: 2008, 1330-57.
23. Fields HW & Christensen JR. Orthodontic procedures after trauma. *J Endod.* 2013; 39(3S): S78-S87.

A comparison of root canal transportation and centering ability between WaveOne® Gold and Protaper Next® files, using micro-computed tomography

SADJ February 2021, Vol. 76 No. 1 p22 - p27

A Gajoum¹, E Patel², IE Munshi³, S Tootla⁴

ABSTRACT

Aim

This study compared the transportation and centering ability of ProTaper Next (PTN) and WaveOne Gold (WOG) files in curved permanent teeth using micro-computed tomography (μ CT).

Methodology

Twenty-four molar teeth with curved roots were divided randomly into two equal groups. The root canals of one group was prepared using PTN files, and the other using WOG files. Pre-instrumentation and post-instrumentation μ CT imaging were taken for all the teeth. The dentine thickness of the pre- and the post-instrumentation cross sections was measured at eight different points at three levels: 3, 5 and 7mm from the apex, by two dentists using image analysis software. The data were analysed using one-way ANOVA, at a 5% significance level.

Results

The transportation in both groups was within the range accepted in the literature. The WOG file exhibited sig-

ACRONYMS

NiTi:	Nickel Titanium
μCT:	Micro-Computed Tomography
CBCT:	Cone-Beam Computed Tomography
PTN:	ProTaper Next
WOG:	WaveOne Gold
KV:	Kilovolt
μA:	Micro Amber
EDTA:	Ethylenediaminetetraacetic Acid

nificantly less root canal transportation compared with the PTN file ($p=0.001$). The WOG file showed a significantly ($p<0.001$) higher mean centering ratio of 0.4286 when compared to that of PTN at 0.2448.

Conclusions

Using a novel technique to measure canal transportation, this study found that the WOG and PTN systems were both suitable for preparation of curved molar root canals, but the WOG showed significantly less canal transportation and better centering ability than the PTN system.

Keywords

Centering ability, Protaper Next, root canal transportation, WaveOne Gold.

INTRODUCTION

Biomechanical preparation of the root canal should result in a tapered preparation that maintains the original path of the canal.¹ This is particularly pertinent in the apical third of curved canals because of the propensity to straighten the canal and the development of complications like, ledge formation, zipping, perforation and root canal transportation.^{2,3}

Root canal transportation and centering ability measurements have been used to compare filing systems and techniques.⁴⁻⁶ Root canal transportation is defined as "Removal of canal wall structure from the outside curve in the apical half of the root canal due to the tendency of

Author affiliations:

- Abdulrag Gajoum:** BDS, MScDent., Department of Conservative Dentistry and Endodontics, Faculty of Dentistry, Alasmarya University, Zliten, Libya.
ORCID Number: 0000-0003-4061-6291
- Ebrahim Patel:** BDS, MScDent, Department of Paediatric & Restorative Dentistry, School of Oral Health Sciences, Faculty of Health Sciences, University of the Witwatersrand, South Africa.
ORCID Number: 0000-0002-7683-4867
- Ismail E Munshi:** BSc, BCHD, MDent, Department of Oral Rehabilitation, School of Oral, Health Sciences, Faculty of Health Sciences, University of the Witwatersrand, South Africa.
- Saidah Tootla:** BCHD, MScDent, Department of Paediatric & Restorative Dentistry, School of Oral Health Sciences, Faculty of Health Sciences, University of the Witwatersrand, South Africa.
ORCID Number: 0000-0001-9014-9455

Corresponding author: Ebrahim Patel

Department of Paediatric & Restorative Dentistry, School of Oral Health Science, 7 York Road, Parktown, Johannesburg, 2193, South Africa.
Email: ebrahim.patel@wits.ac.za

Author contributions:

- Abdulrag Gajoum:** Principal author - 55%
- Ebrahim Patel:** Co-author - 15%
- Ismail E Munshi:** Co-author - 15%
- Saidah Tootla:** Co-author - 15%

files to restore themselves to their original linear shape during canal preparation; may lead to ledge formation and possible perforation".⁷

A centred root canal preparation is another way to express an ideal root canal preparation without transportation. However, it must be kept in mind that the sole use of this method is flawed as it does not account for total circumferential transportation but only transportation in certain directions. The centering ability of a file is its ability to keep centred in the canal during instrumentation and is important for ideal root canal enlargement and to avoid weakening of root canal structure.⁸ While root canal transportation is usually measured in millimetres or micrometres, centering ability is measured using a ratio of 0 to 1. A centering ratio of 1 indicates perfect centering ability whereas, a ratio closer to zero indicates that the root canal wall was unequally prepared.

Over the years, manufacturers of nickel-titanium (NiTi) file systems have introduced various changes to the metallic structure and the designs of the files in order to improve their performance. Different cross sectional and longitudinal designs were produced to minimize apical transportation and to achieve a faster and more predictable canal preparations. These improvements include changes in design, metallurgy, and even the motion which the file is driven with.

ProTaper Next (PTN) file system (Dentsply Tulsa Dental Specialties, USA) is made from M-Wire; a thermo-mechanically treated NiTi metal. PTN was introduced in 2013 and is a continuous rotation system. It contains three crystalline phases: martensite, R-phase, and austenite⁹ and has shown improved cyclic fatigue resistance in comparison with conventional NiTi alloys.¹⁰ The main characteristic of PTN files is that the centre of the file mass is offset, which is claimed to provide a number of advantages, not least of which is the ability to prepare a size of canal that would otherwise require larger and stiffer files.^{11,12} PTN files showed competitive results when compared to other file systems in some studies.^{13,14}

The WaveOne Gold (WOG) reciprocating file system (Dentsply Maillefer, Switzerland) was launched in 2015. After having established an effective glide path, a single file is required to shape the entire canal (in most cases, according to the manufacturer). The files have an off-centred parallelogram cross-section similar to PTN. WOG files have significantly greater flexibility and resistance to torsional stress compared to Reciproc (VDW, Germany) and Twisted File Adaptive (Kerr Endodontics, Glendora, Orange, CA, USA).¹⁵

Recently, methods to measure root canal transportation involving micro-computed tomography (μ CT) and cone-beam computed tomography (CBCT) have become popular.^{13,16-19} Whilst CBCT produces 3-D images, the spatial resolution is considered to be inferior to μ CT which conserves specimens and provides 3-D high resolution images.^{20,21}

The aim of this study was to compare the root canal transportation and centering ability produced by the WOG reciprocating file system and PTN filing system in root

canal treatment using μ CT scans. The study uses a novel eight points measurement technique modified from Gambill et al.⁴ to measure the amount of canal transportation at three different levels along the length of the root canal.

Material and methods

24 extracted maxillary and mandibular first molars with complete root apices were randomly divided into two groups: PTN and WOG. The mesiobuccal and distobuccal roots of maxillary first molars, and the mesiobuccal and mesiolingual root canals of mandibular first molars were used, if they had roots with separate root canals and root canal curvatures of between 20 and 40 degrees.¹³ Excluded were calcified root canals, resorbed roots/root canals, root canals which did not allow a size #8 K-file to be inserted to the major foramen and those that allowed the passive placement of a #15 K-file to within 1 mm of the major foramen. Teeth with fractured roots were also excluded as were those with any previous attempts of endodontic treatment. Ethical clearance for the use of freshly extracted teeth (which were placed immediately after extraction in a 37% formalin solution) was granted by the Human Research Ethics Committee of the University of the Witwatersrand, South Africa; certificate number M160262.

Teeth were placed in a Protrain platform (Simit Dental, supplied by Dentsply, South Africa) and access cavities of sufficient size were prepared using round diamond burs and the Endo Z bur (Dentsply Maillefer, Switzerland). The canals of selected teeth were explored with a size #10 K-file (Dentsply Maillefer, Switzerland), which was advanced passively into the canal until the tip reached the apical foramen. The working length was established while using magnification (Zeiss OPMI Pico dental microscope, 31.25X magnification), from a standardised coronal point to the anatomical apical foramen minus 1 mm. The occlusal surfaces of the teeth were ground down so that the working length of all teeth was 17 mm.

Schneider's method was used to measure the curvature of the root canal, while Pruett's method was used to measure radius of root canal curvature.^{22,23} The angle and the radius of curvature was calculated using the Digi-mizer 4 image analysis software (MedCalc Software®). There-after the teeth were embedded in an acrylic resin block 25 mm depth x 15 mm x 15 mm. Base plate wax was used to prevent the acrylic resin from entering the apical foramen. Pre-instrumentation images were taken using a Nikon Metrology XTH 225/320 LC Micro-CT scanner at a voxel size of 15 μ m, 80 kV and 95 μ A.

For all teeth, the glide path was prepared using the Pro-Glider file (Dentsply Maillefer, Switzerland), according to manufacturer instructions. The X-Smart™ Plus micro-motor (Dentsply Maillefer, South Africa) was used to drive the files and adjusted for the two file systems. One group was instrumented using the primary size (25/07) WOG file according to manufacturer instructions and the other group instrumented using a PTN file X1 (017/0.04) followed by the X2 (025/0.06) file. A #10 K-file was used in both groups between every step to maintain canal patency. 10 to 12 mg of 17% EDTA (RC-Prep, Premier Dental, USA) was loaded on every rotary file to lubricate the root canal.

The individual canals were irrigated with 3 ml of 2.5% sodium hypochlorite between each rotary file. Each instrument was discarded after use in four canals, but any instrument that deformed was discarded immediately. A final irrigation with saline was applied to each root canal and a post-instrumentation μ CT image taken.

Two calibrated assessors compared the pre-and post-instrumentation images using VGSTUDIO MAX 3.0 software (Volume Graphics GmbH, Germany) by measuring the canal cross-sections. When the value between the two raters was different, the mean value of the readings was taken as a final value.

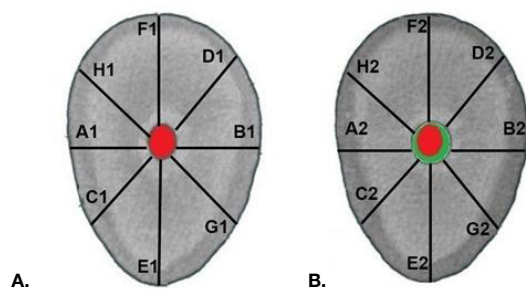


Figure 1. (A) Pre-instrumentation image and measurements taken designated A1 to H1 measured to the unprepared canal (red). (B) post-instrumentation image superimposed and the same measurements taken, designated A2 to H2, measured to the prepared canal (green).

The technique used to measure canal transportation was modified from Gambill et al.⁴ Instead of two measurements, this study used eight measurements (Fig. 1) after superimposition of pre-and post-instrumentation images. The root canal transportation and the centering ability ratio were measured in four directions as the axes A-B, C-D, E-F and G-H.

All readings were taken at each of the three levels from the apex (3, 5 and 7 mm from the root apex). The measurements along each axis were recorded and the values of opposing distances along an axis were subtracted from each other. A result of zero for the equation (e.g. $(A1-A2) - (B1-B2)$) was interpreted as no transportation. A positive value meant that the direction of canal transportation is in the direction of the first part of the equation and a negative value meant the direction of the second part of the equation.

A result of up to 0.15 mm was considered acceptable root canal transportation as most rotary NiTi instruments produce 0.15 mm or less.²⁴ A result of >0.30 mm at the apical end was unacceptable transportation²⁵ and values between 0.15 and 0.30 mm were considered borderline. In order to determine the centering ability, the ratios of the measurements along each axis were calculated, and transposed if necessary to reach a value of between 0 and 1. For example if the result of $\frac{(A1-A2)}{(B1-B2)}$ was more than 1 that meant $\frac{(B1-B2)}{(A1-A2)}$ must be used instead to obtain a value between 0 and 1. Hence the formula was a variation as necessary of the following:

$$CA = \frac{(A1-A2)}{(B1-B2)}, \frac{(C1-C2)}{(D1-D2)}, \frac{(E1-E2)}{(F1-F2)}, \frac{(G1-G2)}{(H1-H2)}$$

A result of 1 means optimal centering ability while a result of zero means no centering ability.

RESULTS

Three X2 PTN files separated during the study, with no separation recorded for the WOG files. Since separation occurred after the full working length had been reached, the three affected teeth were included in the analysis. The average curvature of the canals was 26.43° and 26.54° in the PTN group and the WOG group, respectively. The average radius of curvature in the PTN group was 5.49 mm, and in the WOG group was 5.52 mm.

Root canal transportation and centering ability results were normally distributed and were analysed using a one-way ANOVA, using Stata Version 13.1 (Stata Corp LP, Lakeway Drive, College Station, Texas, USA). Where there was a statistically significant difference, Tukey's multiple comparison post-hoc test was performed to show the site of the difference. A p value of <0.05 was considered statistically significant.

Canal transportation

At all levels of measurement, as well as the overall mean of all measurements, the PTN system was statistically significantly greater than the WOG system (Table 1).

The frequency and direction of root canal transportation at each measurement level is shown in Table 2. At the 3 mm and 5 mm levels, both systems caused greater canal transportation toward the outside, as compared with the inside of canal curvature. However, the opposite was true at the 7 mm sections. The PTN system had a lower range and frequency of samples with no canal transportation (4.2 to 8.3%) than the WOG filing system (8.3 to 33.3%).

Centering ability

The centering ability was significantly different ($p < 0.0001$) between the two systems, with the WOG system performing significantly better overall, and at each of the three levels (Table 3). The WOG also showed consistency between the different levels, whereas the PTN system had significant differences between the 3 mm and 7 mm levels.

DISCUSSION

The aim of this study was to compare the canal transportation and centering ability produced by a rotary file system, PTN, and a reciprocal file system, WOG, in freshly extracted permanent molars with severe canal curvature. In the present study, freshly extracted teeth were used, since they more accurately mimic the clinical situation.²⁶ μ CT scans were used to measure canal transportation and centering ability at three points along the length of the canal, representing the apical, middle and coronal thirds of the canal.

Root canal transportation

The technique that was used to measure root canal transportation was modified from the technique developed by Gambill et al.⁴ which was limited to using two measurements along a single plane. Measurement in only one direction may not be able to adequately show the geometric changes in three dimensions (3D) along the length of the

canal. This study modified Gambill's technique to enable an eight points circumferential analysis that allowed for an enhanced assessment of the mechanical action of the file systems.

Table 2 shows that transportation was observed to have occurred circumferentially, and not just in one direction. This affirms the use of the eight-point measurement technique for assessing canal transportation.

Apical canal transportation of up to 0.15 mm is acceptable and should not be greater than 0.30 mm²⁴ as it negatively affects apical sealing.²⁵ Although the results of this study show that the PTN system produced more canal transportation and poorer centering ability compared to the WOG system, the canal transportation of PTN was within the accepted range and was similar to that obtained by Silva et al.²⁷ (0.061 to 0.144 mm), Zhao et al.¹³ (0.62 mm), and Zanesco et al.¹⁴ (0.055 to 0.081 mm). The results for the WOG system in this study were superior to those reported by van der Vyfer et al.²⁸

This study also confirms the findings from previous studies that the direction of canal transportation in the 3 mm and 5 mm sections under both systems was predominantly toward the outside curvature, while in 7 mm section it was toward the inside of the curvature.^{29,30}

Centering ability

Centering ability, which indicates whether or not the den-

tine removal over the prepared area is spread evenly by the instrument. The ability of an instrument to remain centred within the natural canal path during preparation is essential for adequate enlargement without weakening the root structure.⁸ Good centering ability reduces the risk of transportation, zipping, elbow formation and other preparation errors.

The results of this study concur with the findings by Tamba et al.³¹ who demonstrated that the WaveOne (reciprocation) file (Dentsply Maillefer, Switzerland) remained better centred in the canal than the ProTaper. However, this is in contrast with McRay et al.¹⁷ who showed no significant difference between WaveOne (reciprocation) file and ProTaper Universal (continuous rotation) (Dentsply Maillefer, Switzerland). This could be because WaveOne and ProTaper Universal files have similar design, taper and size and made from the same form of NiTi alloy.

There are several possible explanations for the findings of this study. Zhao et al.¹³ recognised that the centering ability is influenced both by the design features of the instruments (size, taper, flexibility, and type of alloy) as well as the anatomy of the root canal.

The WOG filing system had superior centering ability compared with the PTN filing system, in all three sections along the length of the root canal. This may be attributed to the following factors:

1. The thermal treatment of the WOG file gives it greater

Table 1. Mean ± standard deviation of all measurement for transportation.

System	Level of measurement from the apex			p-values	Mean
	3mm	5mm	7mm		
PTN	0.0621 ± 0.0454	0.0956 ± 0.0753	0.1306 ± 0.9935	p < 0.0001	0.0961 ± 0.0813
WOG	0.0229 ± 0.0240	0.0566 ± 0.0451	0.0931 ± 0.0922	p < 0.0001	0.0575 ± 0.0671
p-values	p < 0.0001	p < 0.0001	p = 0.0073	-	p < 0.001

Table 2. Frequency and direction of root canal transportation at each measurement level of the root canal.

Level	Axis	PTN						WOG					
		Outside		Inside		None		Outside		Inside		None	
3 mm	A – B	19	(79.2%)	4	(16.7%)	1	(4.2%)	12	(50.0%)	4	(16.7%)	8	(33.3%)
	C – D	21	(87.5%)	3	(12.5%)	-	-	14	(58.3%)	6	(25.0%)	4	(16.7%)
	E – F*	16	(66.7%)	8	(33.3%)	-	-	5	(20.8%)	15	(62.5%)	4	(16.7%)
	H – G	11	(45.8%)	11	(45.8%)	2	(8.3%)	12	(50.0%)	7	(29.2%)	5	(20.8%)
5 mm	A – B	20	(83.3%)	4	(16.7%)	-	-	15	(62.5%)	9	(37.5%)	-	-
	C – D	15	(62.5%)	8	(33.3%)	1	(4.2%)	12	(50.0%)	12	(50.0%)	-	-
	E – F*	10	(4.7%)	13	(54.2%)	1	(4.2%)	4	(16.7%)	12	(50.0%)	8	(33.3%)
	H – G	17	(70.8%)	6	(25.0%)	1	(4.2%)	15	(62.5%)	7	(29.2%)	2	(8.3%)
7 mm	A – B	4	(16.7%)	20	(83.3%)	-	-	2	(8.3%)	15	(62.5%)	7	(29.2%)
	C – D	3	(12.5%)	21	(87.5%)	-	-	11	(45.8%)	11	(45.8%)	2	(8.3%)
	E – F*	7	(29.2%)	16	(66.7%)	1	(4.2%)	13	(54.2%)	8	(33.3%)	3	(12.5%)
	H – G	9	(37.5%)	14	(58.3%)	1	(4.2%)	3	(12.5%)	13	(54.2%)	8	(33.3%)

N.B: The E – F (marked with an asterisk *) direction is considered to be neutral. Column labelled none indicates zero transportation.

Table 3. Mean ± standard deviation of all measurement for centering ability.

System	Level of measurement from the apex			p-values	Mean
	3mm	5mm	7mm		
PTN	0.1858 ± 0.2389a	0.2538 ± 0.2986	0.2947 ± 0.2913b	p = 0.0241	0.2448 ± 0.2802
WOG	0.4074 ± 0.3442	0.4302 ± 0.3381	0.4481 ± 0.2938	p = 0.6873	0.4286 ± 0.3254
p-values	p < 0.0001	p = 0.0002	p = 0.0004	-	p < 0.001

^{a,b} Within a row, means without a common superscript differ at P < 0.05. Data are shown as mean ± SD. All the p-values written in bold mean that the values are significantly different.

flexibility, allowing the file to follow the root canal anatomy without considerable resistance, and confirms the findings of Elsaka et al.¹⁵ that the WOG file had significantly greater flexibility and resistance to torsional stress compared to Reciproc and Twisted File Adaptive.

2. The use of a single file requires the gradual introduction of the file to the working length, whereby the file reaches the full working length after the coronal part is partially prepared.
3. The kinematics of the instruments was originally thought to play a role in canal transportation, and reciprocal motion was thought to make the file more centred.³² However, a review of the instrumentation kinematics of engine driven NiTi instruments showed conflicting results on the effect of reciprocating instruments on canal transportation.³³ They attribute the conflicting results to different instruments and methodologies of the respective studies.

This study is in agreement with previous studies that the Primary size of WOG file has a high cyclic fatigue resistance compared to other Ni-Ti files,^{34,35} and recommends the use of the WOG Primary or smaller size file in severely curved root canals to attain superior shaping and centering ability, and to avoid file fracture.

A limitation of this study was that larger sizes of the WOG files were not tested. Caution must be taken when extrapolating these results to the larger file sizes, as they would differ in flexibility. Further studies are needed to evaluate the root shaping ability of the larger sizes of WOG files due to their differing flexibility.

CONCLUSIONS

The WOG and PTN systems were both suitable for preparation of molar root canals with severe curvature, but the WOG showed significantly less canal transportation and better centering ability than the PTN system. This study recommends the use of a novel technique to measure root canal transportation. This technique enables an improved eight point circumferential analysis of the prepared canals.

References

1. Schilder H. Cleaning and shaping the root canal. *Dent Clin North Am.* 1974; 18: 269-96.
2. Sathorn C, Palamara JE, Messer HH. A comparison of the effects of two canal preparation techniques on root fracture susceptibility and fracture pattern. *J Endod.* 2005; 31(4): 283-7.
3. Hargreaves KM, Berman LH. Cohen's pathways of the pulp expert consult. Elsevier Health Sciences. 2015; Oct 2.
4. Gambill JM, Alder M, Carlos E. Comparison of nickel-titanium and stainless steel hand-file instrumentation using computed tomography. *J Endod.* 1996;22(7):369-75.
5. Short JA, Morgan LA, Baumgartner JC. A comparison of canal centering ability of four instrumentation techniques. *J Endod.* 1997; 23(8): 503-7.
6. Gluskin AH, Brown DC, Buchanan LS. A reconstructed computerized tomographic comparison of Ni-Ti rotary GT™ files versus traditional instruments in canals shaped by novice operators. *Int Endod J.* 2001; 34(6): 476-84.
7. Glossary of Endodontic Terms. American Association of Endodontists 9th Edn. Chicago, American Association of Endodontists. 2016. Available at <https://www.aae.org/specialty/clinical-resources/glossary-endodontic-terms/>.
8. Kandaswamy D, Venkateshbabu N, Porkodi I, Pradeep G. Canal-centering ability: An endodontic challenge. *J Conserv Dent.* 2009; 12(1): 3.
9. Alapati SB, Brantley WA, Iijima M, et al. Metallurgical characterization of a new nickel-titanium wire for rotary endodontic instruments. *J Endod.* 2009; 35(11): 1589-93.
10. Johnson E, Lloyd A, Kuttler S, Namerow K. Comparison between a novel nickel-titanium alloy and 508 nitinol on the cyclic fatigue life of ProFile 25/. 04 rotary instruments. *J Endod.* 2008; 34(11): 1406-9.
11. Haapasalo M, Shen Y. Evolution of nickel-titanium instruments: from past to future. *Endod Topics.* 2013; 29(1): 3-17.
12. Saber SE, Nagy MM, Schäfer E. Comparative evaluation of the shaping ability of ProTaper Next, iRaC e and Hyflex CM rotary NiTi files in severely curved root canals. *Int Endod J.* 2015; 48(2): 131-6.
13. Zhao D, Shen Y, Peng B, Haapasalo M. Root canal preparation of mandibular molars with 3 nickel-titanium rotary instruments: a micro-computed tomographic study. *J Endod.* 2014; 40(11): 1860-4.
14. Zanesco C, Só MV, Schmidt S, Fontanella VR, Graziotin-Soares R, Barletta FB. Apical transportation, centering ratio, and volume increase after manual, rotary, and reciprocating instrumentation in curved root canals: analysis by micro-computed tomographic and digital subtraction radiography. *J Endod.* 2017; 43(3): 486-90.
15. Elsaka SE, Elnaghy AM, Badr AE. Torsional and bending resistance of WaveOne Gold, Reciproc and twisted file adaptive instruments. *Int Endod J.* 2017; 50(11): 1077-83.
16. Marzouk AM, Ghoneim AG. Computed tomographic evaluation of canal shape instrumented by different kinematics rotary nickel-titanium systems. *J Endod.* 2013; 39(7): 906-9.
17. McRay B, Cox TC, Cohenca N, Johnson JD, Paranjpe B. A micro-computed tomography-based comparison of the canal transportation and centering ability of ProTaper Universal rotary and WaveOne reciprocating files. *Quintessence Int.* 2014; 45(2): 101-8.
18. Gergi R, Arbab-Chirani R, Osta N, Naaman A. Micro-computed tomographic evaluation of canal transportation instrumented by different kinematics rotary nickel-titanium instruments. *J Endod.* 2014; 40(8): 1223-7.
19. Baek JY, Yoo HM, Park DS, et al. Comparison of the shaping abilities of three nickel-titanium instrumentation systems using micro-computed tomography. *JDS.* 2014; 9(2): 111-7.
20. Freire LG, Gavini G, Cunha RS, Santos MD. Assessing apical transportation in curved canals: comparison between cross-sections and micro-computed tomography. *Braz Oral Res.* 2012; 26(3): 222-7.
21. Shen YA, Cheung GS. Methods and models to study nickel-titanium instruments. *Endod Topics.* 2013; 29(1): 18-41.
22. Schneider SW. A comparison of canal preparations in straight and curved root canals. *Oral Surg Oral Med Oral Pathol.* 1971; 32(2): 271-5.
23. Pruett JP, Clement DJ, Carnes Jr DL. Cyclic fatigue testing of nickel-titanium endodontic instruments. *J Endod.* 1997; 23(2): 77-85.
24. Peters OA. Current challenges and concepts in the preparation of root canal systems: a review. *J Endod.* 2004; 30(8): 559-67.
25. Wu MK, Fan B, Wesselink PR. Leakage along apical root fillings in curved root canals. Part I: effects of apical transportation on seal of root fillings. *J Endod.* 2000; 26(4): 210-6.
26. Nagaraja S, Murthy BS. CT evaluation of canal preparation using rotary and hand Ni-Ti instruments: An *in vitro* study. *J Conserv Dent.* 2010; 13(1): 16.

27. Silva EJ, Pacheco PT, Pires F, Belladonna FG, De-Deus G. Microcomputed tomographic evaluation of canal transportation and centring ability of ProTaper Next and Twisted File Adaptive systems. *Int Endod J.* 2017; 50(7): 694-9.
28. van der Vyver PJ, Paleker F, Vorster M, de Wet FA. Root Canal Shaping Using Nickel Titanium, M-Wire, and Gold Wire: A Micro-computed Tomographic Comparative Study of One Shape, ProTaper Next, and WaveOne Gold Instruments in Maxillary First Molars. *J Endod.* 2019; 45(1): 62-7.
29. Tasdemir T, Aydemir H, Inan U, Ünal O. Canal preparation with Hero 642 rotary Ni-Ti instruments compared with stainless steel hand K-file assessed using computed tomography. *Int Endod J.* 2005; 38(6): 402-8.
30. Pasternak-Júnior B, Sousa-Neto MD, Silva RG. Canal transportation and centring ability of RaCe rotary instruments. *Int Endod J.* 2009; 42(6): 499-506.
31. Tambe VH, Nagmode PS, Abraham S, Patait M, Lahoti PV, Jaju N. Comparison of canal transportation and centering ability of rotary Protaper, One Shape system and Wave One system using cone beam computed tomography: An *in vitro* study. *J Conserv Dent.* 2014; 17(6): 561.
32. Roane JB, Sabala CL, Duncanson Jr MG. The "balanced force" concept for instrumentation of curved canals. *J Endod.* 1985; 11(5): 203-11.
33. Çapar ID, Arslan H. A review of instrumentation kinematics of engine-driven nickel-titanium instruments. *Int Endod J.* 2016; 49(2): 119-35.
34. Topçuoğlu HS, Düzgün S, Aktı A, Topçuoğlu G. Laboratory comparison of cyclic fatigue resistance of WaveOne Gold, Reciproc and WaveOne files in canals with a double curvature. *Int Endod J.* 2017; 50(7): 713-7.
35. Özyürek T. Cyclic fatigue resistance of Reciproc, WaveOne, and WaveOne Gold nickel-titanium instruments. *J Endod.* 2016; 42(10): 1536-9.

Do the CPD questionnaire on page 46

The Continuous Professional Development (CPD) section provides for twenty general questions and five ethics questions. The section provides members with a valuable source of CPD points whilst also achieving the objective of CPD, to assure continuing education. The importance of continuing professional development should not be underestimated, it is a career-long obligation for practicing professionals.



Online CPD in 6 Easy Steps

1. Go to the SADA website www.sada.co.za.
2. Log into the 'member only' section with your unique SADA username and password.
3. Select the CPD navigation tab.
4. Select the questionnaire that you wish to complete.
5. Enter your multiple choice answers. Please note that you have two attempts to obtain at least 70%.
6. View and print your CPD certificate.

Factors influencing apical debris extrusion during endodontic treatment - A review of the literature

SADJ February 2021, Vol. 76 No. 1 p28 - p36

N Predin Djuric¹, PJ van der Vyver², M Vorster³, ZI Vally⁴

INTRODUCTION

The primary cause of a periapical inflammatory lesion is intra-radicular microbial infection.¹ Prevention and elimination of apical periodontitis is achieved through successful endodontic treatment.² Endodontic treatment is designed to maintain and restore the health of the periapical tissues and prevent periapical disease. It may be defined as the combination of mechanical instrumentation of the root canal system with bactericidal irrigation and obturation with an inert material.^{3,4}

Technically, the goal of instrumentation and irrigation is to debride and entirely remove infected tissue debris from the root canal system and create a uniform conical shape that allows medicament delivery and adequate obturation.^{4,5} Microbiologically, the goal of instrumentation and irrigation is to eliminate micro-organisms, reduce their survival in the root canal system and neutralise any antigenic potential of the microbial components remaining in the canal.^{4,6,7}

Keywords

Apical debris extrusion, canal preparation, glide path preparation, instrument design, irrigation, kinematics.

Author affiliations:

1. **Natasa Predin Djuric:** BDS, PG Dip Dent (Endo)(Pret), Department of Odontology, School of Dentistry, University of Pretoria, Pretoria, South Africa and Department of Dentistry, Cecilia Makiwane Hospital, Eastern Cape Department of Health, Eastern Cape, South Africa.
ORCID Number: 0000-0002-0993-856X
2. **Peet J van der Vyver:** BChD, PG Dip Dent (Endo), PG Dip Dent (Aesthet Dent), MSc, PhD (Pret), Department of Odontology, School of Dentistry, University of Pretoria, Pretoria, South Africa.
ORCID Number: 0000-0003-1951-6042
3. **Martin Vorster:** BChD, PG Dip Dent (Endo), MSc (Pret), Department of Odontology, School of Dentistry, University of Pretoria, Pretoria, South Africa.
ORCID Number: 0000-0003-4470-1530
4. **Zunaid I Vally:** BDS, Mdent (Prosthodontics) (Wits), Department of Odontology, School of Dentistry, University of Pretoria, Pretoria, South Africa.
ORCID Number: 0000-0002-2718-4706

Corresponding author: Peet J van der Vyver

Department of Odontology, School of Dentistry, University of Pretoria, Gauteng, South Africa.
Email: peetv@iafrica.com

Author contributions:

1. **Natasa Predin Djuric:** Scientific writing - 50%
2. **Peet J van der Vyver:** Scientific writing and proofreading of the manuscript - 20%
3. **Martin Vorster:** Scientific writing and proofreading of the manuscript - 20%
4. **Zunaid I Vally:** Final editing and proofreading of the manuscript - 10%

Clinical relevance of debris extrusion

During chemo-mechanical preparation, dentinal chips, pulpal fragments, necrotic debris, irrigants and micro-organisms may be inadvertently disseminated from the root canal into periapical tissues,⁸ resulting in postoperative complications such as periapical inflammation, postoperative pain and delayed healing.⁹⁻¹⁰

The amount of material extruded through the apical foramen is one of the main concerns when using an instrumentation technique,¹¹ as periapical extrusion of debris, dentine mud or microbes is thought to play a role in postoperative flare-ups and, even more importantly, in endodontic treatment failures.¹²⁻¹⁴ The frequency of these complications is reported to range between 1.4% and 16%.¹⁰ Preventing debris extrusion therefore plays a significant role in the course of root canal treatment.¹⁵

All instrumentation techniques and files are associated with apical extrusion of debris (**Figure 1**); however, the amount of extruded debris may differ according to the preparation technique used.^{8,16,17} The design of rotary files and the chosen kinematics contributes to accumulating dentinal debris into the flutes of the preparation instruments and directing it coronally toward the canal orifice, lessening apical compaction of debris.¹⁸ Hence, a more favourable postoperative course can be obtained by choosing a technique that lessens apical debris extrusion.^{19,20} Nair et al.²¹ concluded that all instrumentation techniques produce apical extrusion of debris even when the preparation is maintained at the apical terminus.

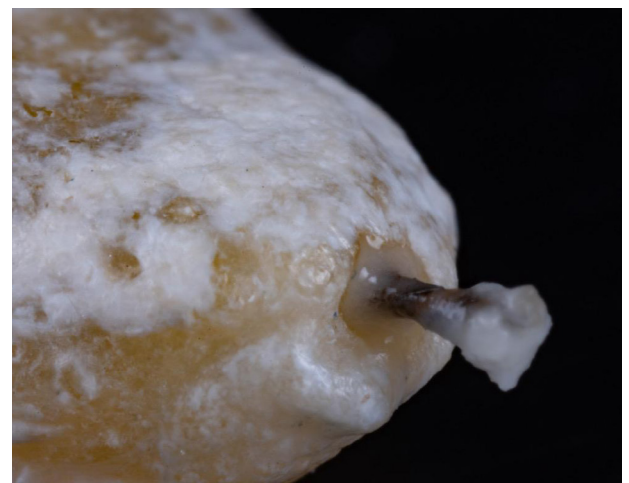

Figure 1. Extrusion of apical debris through root canal foramen during root canal preparation.

Instrumentation techniques

Manual techniques

Ruiz-Hubard et al.²² compared conventional step-back instrumentation to crown-down technique in plastic blocks in both curved and straight canals. The authors found that less debris were apically extruded using the crown-down pressure less technique than with step-back instrumentation. McKendry²³ found lesser amounts of apical debris extrusion after using a balanced forced technique, compared with step-back techniques. Similarly, Al-Omari and Dummer²⁴ found that step-back instrumentation with circumferential filing resulted in the most apical extrusion, whereas crown-down and balanced force techniques formed the smallest amount of debris.

Manual vs. rotary techniques

A mutual finding in the aforementioned studies is that a push-pull canal enlargement action such as filing produces more apical debris than instrumentation techniques that incorporate a rotational force. This led to the hypothesis that engine-driven rotary instruments using the balanced force technique will produce less debris than hand-filing techniques, decreasing potential for periradicular tissue irritation and postoperative sequelae.²⁵ To decrease the amount of apical extrusion of debris, Del Fabbro et al.²⁶ recommend the use of nickel-titanium (NiTi) instrumentation for root canal therapy.

Similarly, numerous studies report that using K-files for root canal instrumentation results in more postoperative pain than does rotary system use.²⁷⁻²⁹ However, Çiçek et al.³⁰ obtained differing results, concluding that the modified step-back technique produced less pain in a 48-hour period than did rotational and reciprocal preparation techniques. Arias et al.²⁷ found that although an increased incidence of postoperative pain is anticipated after manual root canal instrumentation, postoperative pain after rotary canal preparation is expected to last longer. Kashefinejad et al.²⁸ observed a significant difference in postoperative pain when comparing Mtwo (VDW, Munich, Germany) rotary instrumentation to K-file hand instrumentation. In the rotary group, only 13.3% of patients required analgesics as opposed to 56.7% in the hand file group.

Continuous vs. reciprocating single-file systems

Previous studies on postoperative pain have reported inconsistent results from the use of continuous rotary systems and reciprocating systems.^{20,31-33} In analysing postoperative pain, three different studies opted for One Shape (Micro-Mega, Besancon, France) as the file of choice for the rotary single-file instrument group in comparison with different single-file reciprocating instruments.^{29,32,34} Among the three relevant articles, Jain et al.³⁴ and Mollashahi et al.²⁹ report that there was no significant difference in the intensity of postoperative pain between the rotary single-file groups and reciprocating single-file groups. In contrast, a study by Neelakantan and Sharma³² states that compared to the One Shape rotary group, the reciprocating single-file groups exhibited significantly lower postoperative pain intensity.

Single-file vs. multi-file systems

A meta-analysis conducted by Sun et al.³⁵ compared a total of 12 studies on postoperative pain after treatment with engine-driven rotary and reciprocating instruments. The authors concluded that multiple rotary-file systems contributed to a lower incidence of postoperative pain than did reciprocating single-file systems.

A study by Robinson et al.³⁶ found that multiple rotary-file systems yielded cleaner canals with less debris accumulation remaining within the root canal than did reciprocating files. Using micro-computed tomography (micro-CT), this study compared the 3D distribution, quantity, and density of remaining inorganic debris in the mesial roots of mandibular molars after instrumentation. An average of 19.5% debris remained in the canal after single-file reciprocating instrumentation compared to 10.6% with the multi-file rotary technique, showing that reciprocating motion leaves more debris within the canal.

Relationship between bacterial extrusion and amount of debris

A study using a multipurpose analytic approach compared the levels of apically extruded bacterial and hard-tissue debris and intracanal bacterial reduction after root canal preparation. Apical extrusion of bacteria occurred in 90% for XP-endo Shaper (FKG Dentaire, La Chaux-de-Fonds, Switzerland) and 81% for Reciproc (VDW).

Intracanal bacterial reduction was greater when using the XP-endo Shaper. Both reciprocating and continuous rotation techniques produced similar volumes of hard-tissue debris extrusion. Hard-tissue debris extrusion was less frequent than bacterial extrusion and no correlation was observed between the volume of extruded debris and counts of extruded bacteria.³⁷

These contradictory findings justify the need for further investigation of widely used systems.¹¹ Although all instrumentation techniques appear to force intracanal content through the apex into the periapical tissues,¹¹ the amount of debris extrusion may differ according to preparation techniques, kinematics and the design of the rotary file systems.³⁸⁻⁴⁰ Since new instruments and techniques are saturating the market, evaluation of current practices is important.

Rotary kinematics

Three groups of instruments are available for root canal preparation: manually operated instruments, engine-driven rotary instruments and engine-driven reciprocating instruments.⁴¹ The majority of commercially available rotary NiTi root canal systems are primarily driven in a continuous 360° rotation motion around a single axis (Figure 2).^{42,43} Conventional continuous rotation has an increased risk of NiTi instrument fracture caused by torsional and flexural stresses.^{44,45}

Torsional fatigue is the twisting of a metal shaft around its longitudinal axis at one terminus, while the other file terminus is static (Figure 3).⁴⁴ Torsional fracture occurs when a tip or any other part of the instrument binds and locks to the root canal walls, while the rest of the

file continues in rotary motion. Hence it is possible for a practitioner to lessen the intensity of torsional stress by reducing apical force during canal instrumentation. Shaping root canals of smaller diameter generates more torsional stress than shaping larger diameter canals.⁴⁶

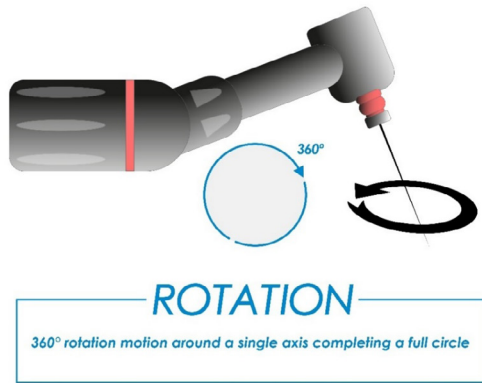


Figure 2. Engine-driven continuous rotation.

Cyclic fatigue ensues when a metal is subjected to recurrent cycles of tension and compression, causing its structure to deteriorate (Figure 4).⁴⁴ Fracture due to flexural fatigue occurs when an instrument that has previously been weakened by metal fatigue is placed under further stress. The instrument does not bind to the root canal walls, but rotates freely until it fractures at the point of maximum flexure.⁴⁶⁻⁴⁸

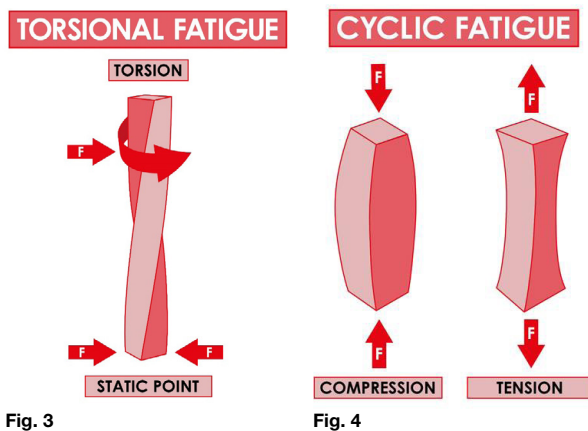


Figure 3. Schematic presentation of forces contributing to torsional fatigue.

Figure 4. Schematic presentation of forces resulting in material cyclic fatigue.

Cyclic fatigue is most likely to occur in a canal with a severe curve and a short radius of curvature,^{44,49} whereas torsional stress might develop in straight canals.⁵⁰ Cyclic fatigue is considered to be the principal cause of NiTi instrument separation.⁵¹

Increasing resistance to file separation has been the main goal of manufacturers in developing the latest NiTi rotary instruments, aimed at improving safety by means of pioneering design and manufacturing processes.^{52,53} To overcome the breakage of endodontic instruments caused by flexural fatigue, reciprocating movement was introduced.⁵⁴ Recent literature data confirms that reciprocating motion can extend the cyclic fatigue resistance of NiTi instruments for longer than continuous rotation.⁵⁴⁻⁵⁶

Reciprocation, defined as any repetitive back-and-forth (up and down or forward and reverse) movement, was originally introduced in endodontics in 1958.^{42,43} Early reciprocating systems used an equal alternating motion of 90° angles and in more recent systems of 30° angles, none of which would complete a full rotation cycle.⁴³ Over time, smaller yet still equal angles of clockwise (CW) and counter-clockwise (CCW) motion were used in M4 hand pieces (SybronEndo, California, USA), Endo-Eze AET (Ultradent, Utah, USA) and Endo-Express (Essential Dental Systems, New Jersey, USA) systems.⁴²

Most recent developments contributed to the introduction of systems based on a new mode of mechanical rotation, a multiple reciprocation motion completing a 360° cycle (Figure 5). In 2010, VDW launched Reciproc and in 2011 Dentsply Sirona launched WaveOne (Dentsply Sirona, Ballaigues, Switzerland), both of which are indicated for use as single-file techniques in automated reciprocation.⁴³




Figure 5. Engine-driven reciprocation.

The kinematics of reciprocating instrumentation is complex. Contrary to continuous rotary motion, the files rotate in a reverse balanced force turning back and forth.^{57,58}

Reciprocating file systems use the alternating movement of unequal CW and CCW cutting angles (different to full sequence continuous rotation files) to prevent torsional fracture. Reciprocating movement aims to reduce this risk by engaging the file in a cutting motion, and then immediately disengaging it in a non-cutting motion.⁵⁹

Reciprocating files currently available on the market are single-file systems designed to have a greater engaging CCW angle (left-cutting) than the disengaging CW angle (non-cutting).⁶⁰ The CCW rotation advances the instrument apically as the dentine of the root canal wall is engaged and cut. This action is followed by a reduced angle CW rotation, which ensures that the instrument disengages before excessive torsional stress is transferred onto the metal alloy, preventing the instrument from binding onto the root canal walls.⁵⁸

A number of studies have compared apical debris extrusion of continuous rotation systems with reciprocating systems. Multiple authors report that reciprocating files extruded more apical debris than rotary files.⁶¹⁻⁶⁴ In contrast, numerous authors found that reciprocating instruments produced less apical debris extrusion than rotary instrumentation.⁶⁵⁻⁶⁸ Various studies also showed no significant difference between the two systems.⁶⁹⁻⁷²

A recent study investigated the amount of apically extruded debris created by the reciprocating file Reciproc blue (VDW) versus continuous rotation files HyFlex EDM (Coltene, Altstätten, Switzerland) and XP-endo Shaper (FKG Dentaire) during root canal preparation at body temperature. The XP-endo Shaper group extruded a significantly smaller amount of debris than Reciproc blue, whereas no significant difference was registered between the HyFlex EDM files and the other NiTi files tested.⁷³ The reasons for the conflicting results could be variability in file design, the number of files used and the canal anatomy differences between the studies.⁷⁴

Apical patency

Throughout canal instrumentation, both pulpal and dental debris can block the apical portion of the root canal and lead to procedural errors.²⁴ A recognised practice for avoiding the accumulation of apical debris is maintaining apical patency, thereby preserving an open pathway between the apical orifice and the periodontal ligament.⁷⁵

Establishing apical patency is the initial step in root canal treatment. The patency file ought to be used prior to irrigation to loosen compacted tissue remnants.⁷⁶ Apical patency is defined as the ability to easily and reproducibly place a small hand file through the minor constriction of the apical foramen. It is followed by glide path preparation, after which root canal enlargement commences.^{77,78} Apical patency is maintained by repetitive recapitulation through the apical constriction with a small K-file with the aim of keeping the root canal free of debris.⁷⁹

Lambrianidis et al.⁸⁰ assessed the role of apical constriction on periapical extrusion of debris/material. They concluded that an enlarged apical constriction resulted in less material being extruded through the foramen. In contrast to this finding, a study by Tinaz et al.³⁹ showed an increase in the amount of apically extruded material with an increase in the diameter of the apical patency. The conflicting findings can be attributed to the study design. In the study by Lambrianidis et al.⁸⁰ the canal instrumentation was executed in two stages using a step-back technique. The root canals were initially only instrumented up to the apical constriction. In the second phase of canal preparation, the apical constriction was intentionally enlarged. The canals were already enlarged in phase one and this could have allowed easier elimination of debris, as the coronal portion of the canal space was wider in phase two.

A patency file should be used with care, because it may force accumulated debris apically with the risk of inoculating microbes into the periapical region.⁸¹ However, newly available evidence indicates that maintaining apical patency does not increase postoperative pain or the rate of postoperative flare-ups.⁸²

Glide path

Glide path preparation is an adjunctive preliminary procedure prior to canal instrumentation.⁷⁸ Although there is no current consensus on the definition of a glide path,⁸³ it is commonly described as “a smooth radicular tunnel from the canal orifice to the physiologic terminus (apical

foraminal constriction)”.⁸⁴ Before canal preparation, a reproducible glide path should be created to minimise procedural accidents and improve the shaping ability of the final canal shaping system.^{2,85} Initial glide path creation assists in minimising preparation times and preserves the original anatomy with little modifications and aberrations to the root canal curvature,⁸³ improving the outcome of endodontic treatment.⁷⁸

Manual and rotary glide path instruments are the first files to negotiate narrow and calcified root canal systems, hence they encounter high levels of torsional stress.⁴⁴ If the instrument tip cross-section is larger than the canal width, instrument blades can bind into the root canal walls. This is known as taper locking. Creating a glide path decreases the contact area between the shaping file and root canal walls, reducing the likelihood of taper locking and subsequently decreasing torsional stress.⁸⁶

The creation of a glide path has been recognised as crucially important in reducing the incidence of instrument fracture due to reduced torsional and flexural stress on the root canal instrument.⁸⁷ Glide path preparation increases the efficacy of root canal preparation, as it produces a reproducible tunnel in which rotary preparation instruments can run smoothly with reduced incidences of instrument fracture or canal aberrations.^{83,87-89}

One of the risks of any instrumentation technique is apical debris extrusion, which increases the possibility of postoperative inflammatory reaction.⁹⁰ Post-treatment complications are decreased because much of the pulp, bacteria and related irritants are removed during pre-enlargement procedures. Passing files through underprepared canals coronally pushes more irritants beyond the apex and generates more postoperative exacerbations. On the other hand, passing files through a cleaned pre-enlarged preparation equates to less debris being unintentionally inoculated periapically.²⁵

Topçuoğlu et al.⁹¹ demonstrated that creating a glide path prior to canal instrumentation reduced the amount of apically extruded debris during canal preparation in curved canals. More recently, Gunes and Yeter⁹² found that glide path preparation before root canal preparation with a Primary WaveOne Gold file (Dentsply Sirona) had no effect on apical debris extrusion.

The study compared the amount of apically extruded debris after using multiple glide path files, before preparing curved root canals with the reciprocating Primary WaveOne Gold single file. They found that K-files showed a significantly higher amount of debris extrusion than One G glide path files (Micro-Mega), which could be explained by the fact that the tip diameter of One G files (0.14mm) is smaller than the other glide path files used in the study.

However, there was no significant difference between the K-files and the other rotary glide path files in terms of apical debris extrusion.⁹² These results could correlate with the finding of Tinaz et al.³⁹ that the quantity of apically extruded debris increased in teeth with a greater apical patency during both manual instrumentation with K-files and engine-driven rotary instrumentation with Pro-File .04 Taper Series 29 (Dentsply Sirona). Regardless of

the techniques used, there was a tendency for greater apical debris extrusion as the diameter of apical patency increased.

More debris is generally extruded during the main shaping procedure, than during the glide path preparation procedure. However in the latter, although the amount of debris may be small, this initially extruded debris may contain higher toxicity than debris extruded later by the shaping instrument.¹¹

Instrument design

The objective of biomechanical preparation is to remove vital and necrotic pulp tissue, infected radicular dentine, micro-organisms and microbial toxins from the root canal system.⁹³ Most current mechanical root canal instrumentation systems propose single- or multiple-file systems to prepare root canals to a minimal dimension.⁹⁴ The standard enlargement of the root canal is typically associated with an ISO tip size of 25 and either a variable taper or a continuous 6% taper.^{5,95}

It is important to note that the design of rotary files and the selected motion contribute to collecting dentinal debris in the flutes of the instruments and directing it coronally toward the canal orifice, lessening the compaction of debris in the root canal.¹⁸ Inconsistency has been noted between different mechanical systems in terms of debris extrusion.⁴⁰ Apical debris extrusion variability is presumed to be caused by differences in cross-section and cutting blade design, taper, tip type, configuration, concepts of use, flexibility, alloy, number of files used, kinematics, and cutting efficacy.⁹⁶

In search of superior NiTi alloy properties, manufacturers have used new manufacturing methods, postproduction material heat treatments and different cross-sectional designs. NiTi alloys used for endodontic files can be grouped into instruments that primarily comprise the austenite structural phase (conventional NiTi, M-Wire, R-Phase) and those predominantly comprising the martensite structural phase (CM Wire, Gold and Blue heat-treated NiTi).⁹⁷

Heat-treated NiTi alloys include M-Wire, R-Phase and CM-Wire. M-wire has three crystalline phases: deformed and micro-twinned martensite, R-Phase, and austenite. M-Wire and R-Phase instruments show greater resistance to cyclic fatigue and superior flexibility than conventional NiTi files. CM-Wire uses the stable martensite phase because the austenite finishing temperature is above working temperature. CM-Wire reverts to its original shape after heat application or autoclaving.⁹⁸

Currently available rotary NiTi file endodontic systems cater for both continuous rotation and reciprocating motion. The most widely used continuous rotation systems are ProTaper Universal (Dentsply Sirona), ProTaper Next (Dentsply Sirona), Revo-S (Micro-Mega), One Shape (Micro-Mega), One Curve (Micro-Mega), HyFlex CM (Coltene), HyFlex EDM (Coltene) and TruNatomy (Dentsply Sirona). WaveOne (Dentsply Sirona), WaveOne Gold (Dentsply Sirona), Reciproc (VDW) and Reciproc blue (VDW) are the main endodontic file brands that are used in reciprocation.⁹⁹

Clockwise/forward/right-cutting reciprocation

Reciprocating motion is an evolution of the balanced force technique offering an alternative method to prevent procedural errors during root canal instrumentation.¹⁰⁰ In theory, the alternating changes in the direction of rotation reduce the number of cycles of the instrument and therefore the cyclic fatigue on the instrument compared with that imposed when instruments are used in a consistent rotating motion.^{55,101} Based on several studies, root canal shaping with reciprocating motion has been postulated to offer superior fracture resistance.^{54,101-104}

Paqué¹⁰⁵ demonstrated that the F2 ProTaper Universal in reciprocating motion is as efficient as the conventional ProTaper Universal full sequence (Dentsply Sirona) technique in continuous motion. A study by Espir¹⁰⁶ produced comparable results, showing that CW reciprocation motion with Mtwo (VDW) results in effective canal preparation.

All continuous rotation systems are designed to cut in a CW direction (right-cutting). The rotary CW cutting instrument may neither cut nor infiltrate the canal walls if used in CCW reciprocating motion. Since the reciprocating file systems have been designed to cut in a CCW direction (left-cutting), the CCW angle of motion is greater than the CW angle.¹⁰⁷ Reciprocating motion with CW rotation greater than the CCW motion could allow the use of a larger number of conventional rotary file systems, as the flutes of the majority of systems are designed for continuous CW rotation.¹⁰⁶

In 2016, two studies evaluated the effects of kinematics on apical debris extrusion. These studies assessed the same instruments, used in the same sequence. Movement kinematics was the only variable between different groups, therefore excluding other variables such as the instrumentation sequence, instrument alloy and instrument design. The authors concluded that movement kinematics significantly affected the amount of apically extruded debris.^{108,109} Karatas et al.¹⁰⁸ evaluated the influence of different movement kinematics (TF Adaptive motion, 90° CW–30° CCW, 150° CW–30° CCW and continuous rotation) on apical debris extrusion using Twisted File Adaptive instruments (SybronEndo). According to their findings, when the reciprocation range increased apical debris extrusion decreased.

The decreased reciprocation range in the 90° CW–30° CCW group produced more debris extrusion. The increased reciprocation range in the 150° CW–30° CCW group could have generated less extrusion because more debris was transported coronally by the file acting as a screw conveyor due to the enlarged reciprocation range. Arslan et al.¹⁰⁹ measured the amount of apically extruded debris using Reciproc (VDW) instruments with various kinematics (150° CCW–30° CW, 270° CCW–30° CW, 360° CCW–30° CW and continuous rotation). The results of their study revealed that the 150° CCW–30° CW and 270° CCW–30° CW reciprocating motions extruded significantly less debris than continuous rotation.

Solutions and debris extrusion

Irrigation is an essential part of the debridement sequence. Both dentine debris and the smear layer adhering to

the canal walls are created by the engagement of endodontic instruments during preparation,¹¹⁰ and should be eliminated from the root canal system to improve outcome prognosis. Although debris and smear layer removal is primarily achieved by irrigation,¹¹¹ approximately half of the debris created during instrumentation cannot be removed from the canal system.¹¹⁰

Irrigant infiltration of the apical portion of the canal is essential in order to clean and keep it free of debris,⁸² reducing the risk of blockages and apical debris extrusion.⁹ Irrigants often do not reach the apical third of the canal due to the vapour lock effect. An effective hydrodynamic effect can be produced by agitating the irrigant and significantly improving the exchange and efficiency of any desired solution.¹¹²

In a recent study by Gupta et al.¹¹³ different irrigation agitation techniques showed apical extrusion of both debris and irrigant. The mean amounts of apically extruded irrigant and debris were greater in agitation groups than in the no-agitation control groups. This could be due to greater turbulence caused within the canal as a result of improved irrigant displacement.

Elimination of dentine and pulpal debris is thought to be improved with frequent and abundant irrigation.¹¹⁴ Debatable results were found when investigating the relationship between the amount of apically extruded debris and irrigant use. Hinrichs et al.¹¹⁵ and Ferraz et al.¹¹⁶ found a positive correlation, while Myers and Montgomery¹¹⁷ and Tinaz et al.³⁹ reported no correlation.

Sodium hypochlorite (NaOCl) solution has the ability to dissolve organic material,¹¹⁸ hence displaying great potential to remove the debris produced during chemomechanical root canal preparation.¹¹⁹ It also exhibits antimicrobial properties, leading to successful decontamination of the root canal system.¹²⁰ Although highly cytotoxic to the periapical tissues in high concentrations,⁷⁶ it is the most widely used irrigant in endodontic treatment.¹²¹

In addition to dentinal debris collection within the root canal, endodontic instrumentation techniques produce a smear layer that accumulates on the root canal walls and blocks the openings of dentinal tubules. The smear layer consists of organic and inorganic substances including dentinal filings, fragments of odontoblastic processes and micro-organisms.¹²²

Ethylenediaminetetraacetic acid (EDTA) is a chelating agent used as a final irrigant to remove the potentially infected smear layer and open calcified canals due to its decalcifying properties. Although NiTi instrument manufacturers recommend using EDTA preparations for lubrication during canal instrumentation, contact between EDTA and the periapical tissue cannot be excluded.¹²³

A study by Cruz et al.¹²⁴ investigated whether the use of a paste containing EDTA during cleaning and shaping of the root canal helped to eliminate debris. In the first group, NaOCl was used during canal preparation and final irrigation was achieved with 17% liquid EDTA. In the second group, NaOCl was also employed as the irrigating solution, but Glyde Root Canal Conditioner (Dentsply Sirona)

was used with every instrument. Likewise, final irrigation was performed with 17% liquid EDTA. The authors concluded that the use of Glyde Root Canal Conditioner (Dentsply Sirona) during mechanical instrumentation resulted in increased accumulation of debris in the apical third of the root canals.

De Deus et al.¹²⁵ took high-resolution 3D micro-CT scans of teeth to register and quantify the amount of accumulated hard-tissue debris within the root canal system following canal instrumentation. Hard-tissue debris occupied 34.6% of the canal volume when no irrigant was used during canal preparation. Irrigation with bidistilled water resulted in 16% volume of debris, while irrigation with NaOCl followed by EDTA resulted in 11.3% volume of debris remaining within the root canal system. Markedly more debris accumulated in the non-irrigated specimen, undoubtedly due to the lack of liquid flow.

CONCLUSION

Apart from instrumentation techniques, instrument design and irrigation methods, kinematics plays an important role in apical extrusion of debris and should be viewed as a key factor in the complex aetiology of debris extrusion. Careful selection of endodontic instruments and the utilization of alternative rotary kinematics in a clinical setting might aid in the reduction of debris extrusion and subsequently limit irritation to peripapal tissue.

References

1. Möller AJR, Fabricius L, Dahlén G, Öhman AE, et al. Influence on periapical tissues of indigenous oral bacteria and necrotic pulp tissue in monkeys. *Eur J Oral Sci.* 1981; 89(6): 475-84.
2. Berutti E, Negro AR, Lendini M, Pasqualini D. Influence of manual preflaring and torque on the failure rate of ProTaper rotary instruments. *J Endod.* 2004; 30(4): 228.
3. Ng YL, Mann V, Rahbaran S, Lewsey J, et al. Outcome of primary root canal treatment: systematic review of the literature - Part 2. Influence of clinical factors. *Int Endod J.* 2008; 41(1): 6-31.
4. Haapasalo M, Endal U, Zandi H, Coil JM. Eradication of endodontic infection by instrumentation and irrigation solutions. *Endod Topics.* 2005; 10(1): 77-102.
5. Peters OA. Current challenges and concepts in the preparation of root canal systems: A review. *J Endod.* 2004; 30(8): 559-67.
6. Riitano F. Anatomic Endodontic Technology (AET) - a crown-down root canal preparation technique: basic concepts, operative procedure and instruments. *Int Endod J.* 2005; 38(8): 575-87.
7. Wang J, Jiang Y, Chen W, Zhu C, et al. Bacterial flora and extraradicular biofilm associated with the apical segment of teeth with post-treatment apical periodontitis. *J Endod.* 2012; 38(7): 954-9.
8. Kustarcı A, Akpınar KE, Er K. Apical extrusion of intracanal debris and irrigant following use of various instrumentation techniques. *Oral Surg, Oral Med, Oral Pathol, Oral Radiol, Endodontol.* 2008; 105(2): 257-62.
9. Siqueira JF. Microbial causes of endodontic flare-ups. *Int Endod J.* 2003; 36(7): 453-63.
10. Siqueira JF, Jr., Rôças IN, Favieri A, Machado AG, et al. Incidence of postoperative pain after intracanal procedures based on an antimicrobial strategy. *J Endod.* 2002; 28(6): 457-60.
11. Tanalp J, Güngör T. Apical extrusion of debris: a literature review of an inherent occurrence during root canal treatment. *Int Endod J.* 2014; 47(3): 211-21.

12. Yusuf H. The significance of the presence of foreign material periapically as a cause of failure of root treatment. *Oral Surg Oral Med Oral Pathol.* 1982; 54(5): 566-74.
13. Sjogren U, Hagglund B, Sundqvist G, Wing K. Factors affecting the long-term results of endodontic treatment. *J Endod.* 1990; 16(10): 498-504.
14. Siqueira JF. Aetiology of root canal treatment failure: why well-treated teeth can fail. *Int Endod J.* 2001; 34(1): 1-10.
15. Torabinejad M, Walton RE. Managing endodontic emergencies. *J Am Dent Assoc (1939).* 1991; 122(5): 99,101,3.
16. Bürklein S, Schäfer E. Apically extruded debris with reciprocating single-file and full-sequence rotary instrumentation systems. *J Endod.* 2012; 38(6): 850-2.
17. Kirchhoff AL, Fariniuk LF, Mello I. Apical extrusion of debris in flat-oval root canals after using different instrumentation systems. *J Endod.* 2015; 41(2): 237-41.
18. Beeson TJ, Hartwell GR, Thornton JD, Gunsolley JC. Comparison of debris extruded apically in straight canals: Conventional filing versus profile .04 Taper series 29. *J Endod.* 1998; 24(1): 18-22.
19. Buldur B, Hascizmeci C, Aksoy S, Nur Aydin M, et al. Apical extrusion of debris in primary molar root canals using mechanical and manual systems. *Eur J Paediatr Dent.* 2018; 19(1): 16-20.
20. Kherlakian D, Cunha RS, Ehrhardt IC, Zuolo ML, et al. Comparison of the incidence of postoperative pain after using 2 reciprocating systems and a continuous rotary system: A prospective randomized clinical trial. *J Endod.* 2016; 42(2): 171-6.
21. Nair PNR, Henry SP, Cano V, Vera J. Microbial status of apical root canal system of human mandibular first molars with primary apical periodontitis after "one-visit" endodontic treatment. *Oral Surg, Oral Med, Oral Pathol, Oral Radiol Endodontol.* 2005; 99(2): 231-52.
22. Ruiz-Hubard EE, Gutmann JL, Wagner MJ. A quantitative assessment of canal debris forced periapically during root canal instrumentation using two different techniques. *J Endod.* 1987; 13(12): 554-8.
23. McKendry DJ. Comparison of balanced forces, endosonic, and step-back filing instrumentation techniques: quantification of extruded apical debris. *J Endod.* 1990; 16(1): 24-7.
24. Al-Omari MAO, Dummer PMH. Canal blockage and debris extrusion with eight preparation techniques. *J Endod.* 1995; 21(3): 154.
25. Reddy SA, Hicks ML. Apical extrusion of debris using two hand and two rotary instrumentation techniques. *J Endod.* 1998; 24(3): 180-3.
26. Del Fabbro M, Afrashtehfar KI, Corbella S, El-Kabbaney A, et al. *In vivo* and *in vitro* effectiveness of rotary nickel-titanium vs manual stainless steel instruments for root canal therapy: Systematic review and meta-analysis. *J Evid Based Dent Pract.* 2018; 18(1): 59-69.
27. Arias A, de la Macorra JC, Azabal M, Hidalgo JJ, et al. Prospective case controlled clinical study of post-endodontic pain after rotary root canal preparation performed by a single operator. *J Dent.* 2015;43(3):389-95.
28. Kashefinejad M, Harandi A, Eram S, Bijani A. Comparison of single visit post endodontic pain using Mtwo rotary and hand K-file instruments: A Randomized Clinical Trial. *J Dent (Tehran).* 2016; 13(1): 10-7.
29. Mollashahi NF, Saberi EA, Havaei SR, Sabeti M. Comparison of postoperative pain after root canal preparation with two reciprocating and rotary single-file systems: A randomized clinical trial. *Ir Endod J.* 2017; 12(1): 15-9.
30. Çiçek E, Koçak MM, Koçak S, Sağ-lam BC, et al. Postoperative pain intensity after using different instrumentation techniques: a randomized clinical study. *J Appl Oral Sci: revista FOB.* 2017; 25(1): 20-6.
31. Gambarini G, Testarelli L, De Luca M, Milana V, et al. The influence of three different instrumentation techniques on the incidence of postoperative pain after endodontic treatment. *Ann Stomatol (Roma).* 2013; 4(1): 152-5.
32. Neelakantan P, Sharma S. Pain after single-visit root canal treatment with two single-file systems based on different kinematics - a prospective randomized multicenter clinical study. *Clin Oral Investig.* 2015; 19(9): 2211-7.
33. Relvas JBF, Bastos MMB, Marques AAF, Garrido ADB, et al. Assessment of postoperative pain after reciprocating or rotary NiTi instrumentation of root canals: A randomized, controlled clinical trial. *Clin Oral Investig.* 2016; 20(8): 1987-93.
34. Jain N, Pawar A, Gupta A. Incidence and severity of post-operative pain after canal instrumentation with reciprocating system, continuous rotary single file system, versus SAF system. *Endod practice.* 2016; 10: 153-60.
35. Sun C, Sun J, Tan M, Hu B, et al. Pain after root canal treatment with different instruments: A systematic review and meta-analysis. *Oral Dis.* 2018; 24(6): 908-19.
36. Robinson JP, Lumley PJ, Cooper PR, Grover LM, et al. Reciprocating root canal technique induces greater debris accumulation than a continuous rotary technique as assessed by 3-dimensional micro-computed tomography. *J Endod.* 2013; 39(8): 1067-70.
37. Alves FRF, Paiva PL, Marceliano-Alves MF, Cabreira LJ, et al. Bacteria and hard tissue debris extrusion and intracanal bacterial reduction promoted by XP-endo Shaper and Reciproc instruments. *J Endod.* 2018; 44(7): 1173-8.
38. Caviedes-Bucheli J, Castellanos F, Vasquez N, Ulate E, et al. The influence of two reciprocating single-file and two rotary-file systems on the apical extrusion of debris and its biological relationship with symptomatic apical periodontitis. A systematic review and meta-analysis. *Int Endod J.* 2016; 49(3): 255-70.
39. Tinaz AC, Alacam T, Uzun O, Maden M, et al. The effect of disruption of apical constriction on periapical extrusion. *J Endod.* 2005; 31(7): 533-5.
40. Tanalp J, Kaptan F, Sert S, Kayahan B, et al. Quantitative evaluation of the amount of apically extruded debris using 3 different rotary instrumentation systems. *Oral Surg, Oral Med, Oral Pathol, Oral Radiol, Endodontol.* 2006; 101(2): 250-7.
41. Hargreaves K, Berman L, Rotstein I. Cohen's pathways of the pulp. Eleventh edition. ed: Mosby: Elsevier Health Sciences; 2015.
42. Jain P. Current therapy in endodontics. Ames, Iowa: Wiley Blackwell; 2016.
43. Webber J. Shaping canals with confidence: WaveOne GOLD single-file reciprocating system. *Roots.* 2015(1): 34-40.
44. Sattapan B, Nervo GJ, Palamara JEA, Messer HH. Defects in rotary nickel-titanium files after clinical use. *J Endod.* 2000; 26(3): 161-5.
45. Sotokawa T. An analysis of clinical breakage of root canal instruments. *J Endod.* 1988; 14(2): 75-82.
46. Sattapan B, Palamara JEA, Messer HH. Torque during canal instrumentation using rotary nickel-titanium files. *J Endod.* 2000; 26(3): 156-60.
47. Martín B, Zelada G, Varela P, Bahillo JG, et al. Factors influencing the fracture of nickel-titanium rotary instruments. *Int Endod J.* 2003; 36(4): 262-6.
48. Gabel WP, Hoen M, Steiman HR, Pink FE, et al. Effect of rotational speed on nickel-titanium file distortion. *J Endod.* 1999; 25(11): 752-4.
49. Pruett JP, Clement DJ, Carnes DL. Cyclic fatigue testing of nickel-titanium endodontic instruments. *J Endod.* 1997; 23(2): 77-85.
50. Plotino G, Grande NM, Melo MC, Bahia MG, et al. Cyclic fatigue of NiTi rotary instruments in a simulated apical abrupt curvature. *Int Endod J.* 2010; 43(3): 226-30.
51. Parashos P, Messer HH. Rotary NiTi instrument fracture and its consequences. *J Endod.* 2006; 32(11): 1031-43.
52. Tripi TR, Bonaccorso A, Condorelli GG. Cyclic fatigue of different nickel-titanium endodontic rotary instruments. *Oral Surg, Oral Med, Oral Pathol, Oral Radiol, Endodont.* 2006; 102(4): 106-14.

53. Gambarini G, Grande NM, Plotino G, Somma F, et al. Fatigue resistance of engine-driven rotary nickel-titanium instruments produced by new manufacturing methods. *J Endod.* 2008; 34(8): 1003-5.
54. De-Deus G, Moreira EJJ, Lopes HP, Elias CN. Extended cyclic fatigue life of F2 ProTaper instruments used in reciprocating movement. *Int Endod J.* 2010; 43(12): 1063-8.
55. You S-Y, Bae K-S, Baek S-H, Kum K-Y, et al. Lifespan of one nickel-titanium rotary file with reciprocating motion in curved root canals. *J Endod.* 2010; 36(12): 1991-4.
56. Gambarini G, Gergi R, Naaman A, Osta N, et al. Cyclic fatigue analysis of twisted file rotary NiTi instruments used in reciprocating motion. *Int Endod J.* 2012; 45(9): 802-6.
57. Jonker C, van der Vyver PJ. Reciprocating instruments in endodontics: A review of the literature. *S Afr Dent J.* 2014; 69(9): 404-9.
58. Webber J, Machtou P, Pertot W, Kuttler S, et al. The WaveOne single-file reciprocating system. *Roots.* 2011; 1: 28-33.
59. Gupta R, Tomer A, Rohilla S. Single file endodontics: Boon or myth? *Asian Pacific J Health Sci.* 2016; 3(2): 102-5.
60. Fidler A. Kinematics of 2 reciprocating endodontic motors: The difference between actual and set values. *J Endod.* 2014; 40(7): 990-4.
61. Bürklein S, Benten S, Schäfer E. Quantitative evaluation of apically extruded debris with different single-file systems: Reciproc, F360 and OneShape versus Mtwo. *Int Endod J.* 2014; 47(5): 405-9.
62. Bürklein S, Schäfer E. Apically extruded debris with reciprocating single-file and full-sequence rotary instrumentation systems. *J Endod.* 2012; 38(6): 850-2.
63. Toyoglu M, Altunbas D. Influence of different kinematics on apical extrusion of irrigant and debris during canal preparation using K3XF instruments. *J Endod.* 2017; 43(9): 1565-8.
64. Surakanti J, Venkata RC, Vemisetty H, Dandolu R, et al. Comparative evaluation of apically extruded debris during root canal preparation using ProTaper, Hyflex and Waveone rotary systems. *J Conserv Dent.* 2014; 17(2): 129.
65. Arslan H, Dog-anay E, Alsancak M, Çapar ID, et al. Comparison of apically extruded debris after root canal instrumentation using Reciproc instruments with various kinematics. *Int Endod J.* 2016; 49(3): 307-10.
66. Üstün Y, Çanakçı BC, Dinçer AN, Er O, et al. Evaluation of apically extruded debris associated with several Ni-Ti systems. *Int Endod J.* 2015; 48(7): 701-4.
67. Dincer AN, Er O, Canakci BC. Evaluation of apically extruded debris during root canal retreatment with several NiTi systems. *Int Endod J.* 2015; 48(12): 1194-8.
68. Silva EJ, Carapiá MF, Lopes RM, Belladonna FG, et al. Comparison of apically extruded debris after large apical preparations by full-sequence rotary and single-file reciprocating systems. *Int Endod J.* 2016; 49(7): 700-5.
69. Ozsu D, Karatas E, Arslan H, Topcu M. Quantitative evaluation of apically extruded debris during root canal instrumentation with ProTaper Universal, ProTaper Next, WaveOne, and self-adjusting file systems. *Eur J Dent.* 2014; 8(4): 504-8.
70. Koçak S, Koçak MM, Sag-lam BC, Türker SA, et al. Apical extrusion of debris using self-adjusting file, reciprocating single-file, and 2 rotary instrumentation systems. *J Endod.* 2013; 39(10): 1278-80.
71. Vivekanandhan P, Subbiya A, Mitthra S, Karthick A. Comparison of apical debris extrusion of two rotary systems and one reciprocating system. *J Conserv Dent.* 2016; 19(3): 245-9.
72. Kirchhoff AL, Fariniuk LF, Mello I. Apical extrusion of debris in flat-oval root canals after using different instrumentation systems. *J Endod.* 2015; 41(2): 237-41.
73. Uslu Gla, Özyürek T, Yılmaz K, Gündog-ar M, et al. Apically extruded debris during root canal instrumentation with Reciproc Blue, HyFlex EDM, and XP-endo Shaper nickel-titanium files. *J Endod.* 2018; 44(5): 856-9.
74. Salloum S, Torbey C, Bassam S, Dib C. Reciprocal and continuous rotation is two sides of the same coin. *J Dent Health Oral Disord Ther.* 2018; 9(3).
75. Flanders D. Endodontic patency. How to get it. How to keep it. Why it is so important. *N Y State Dent J.* 2002; 68: 30-2.
76. Hülsmann M, Schäfer E. Apical patency: Fact and fiction-a myth or a must? A contribution to the discussion. *Endo.* 2009; 3: 285-307.
77. Mounce RE, Glassman G. Principle driven cleaning, shaping and obturation in orthograde first-time endodontic treatment. *Oral Health.* 2010; 100(5): 40-9.
78. Paleker F, van der Vyver PJ. Glide path enlargement of mandibular molar canals by using K-files, the ProGlider File, and G-Files: A comparative study of the preparation times. *J Endod.* 2017; 43(4): 609-12.
79. American Association of Endodontists (AAE). Glossary of endodontic terms. 9th ed: American Association of Endodontists; 2015.
80. Lambrianidis T, Tosounidou E, Tzoanopoulou M. The effect of maintaining apical patency on periapical extrusion. *J Endod.* 2001; 27(11): 696-8.
81. Izu KH, Thomas SJ, Zhang P, Izu AE, et al. Effectiveness of sodium hypochlorite in preventing inoculation of periapical tissues with contaminated patency files. *J Endod.* 2004; 30(2): 92-4.
82. Yaylali IE, Demirci GzK, Kurnaz S, Celik G, et al. Does maintaining apical patency during instrumentation increase post-operative pain or flare-up rate after nonsurgical root canal treatment? A systematic review of randomized controlled trials. *J Endod.* 2018; 44(8):1228-36.
83. Hartmann RC, Peters OA, de Figueiredo JAP, Rossi-Fedele G. Association of manual or engine-driven glide path preparation with canal centring and apical transportation: a systematic review. *Int Endod J.* 2018; 51(11): 1239-52.
84. West JD. The endodontic glidepath: "Secret to rotary safety". *Dent Today.* 2010; 29(9): 90-3.
85. Elnaghy AM, Elsaka SE. Evaluation of root canal transportation, centering ratio, and remaining dentin thickness associated with ProTaper Next instruments with and without glide path. *J Endod.* 2014; 40(12): 2053-6.
86. Rodrigues E, De-Deus G, Souza E, Silva EJ. Safe mechanical preparation with reciprocation movement without glide path creation: result from a pool of 673 root canals. *Braz Dent J.* 2016; 27(1): 22-7.
87. Patiño PV, Biedma BM, Liébana CR, Cantatore G, et al. The influence of a manual glide path on the separation rate of NiTi rotary instruments. *J Endod.* 2005; 31(2): 114-6.
88. Cassim I, van der Vyver PJ. The importance of glide path preparation in endodontics: a consideration of instruments and literature. *S Afr Dent J.* 2013; 68(7): 324-7.
89. Khatavkar R, SH. Importance of patency in endodontics. *Endodontology.* 2010; 22: 85-91.
90. Seltzer S, Naidorf IJ. Flare-ups in endodontics: I. Etiological factors. *J Endod.* 1985; 11(11): 472-8.
91. Topçuoğ-lu HS, Düzgün S, Akpek F, Topçuoğ-lu G, et al. Influence of a glide path on apical extrusion of debris during canal preparation using single-file systems in curved canals. *Int Endod J.* 2016; 49(6): 599-603.
92. Gunes B, Yeter Y. Effects of different glide path files on apical debris extrusion in curved root canals. *J Endod.* 2018; 44(7): 1191-4.
93. Basmadjian-Charles CL, Farge P, Bourgeois DM, Lebrun T. Factors influencing the long-term results of endodontic treatment: a review of the literature. *Int Dent J.* 2002; 52(2): 81-6.
94. Plotino G, Özyürek T, Grande NM, Gündog-ar M. Influence of size and taper of basic root canal preparation on root canal cleanliness: A scanning electron microscopy study. *Int Endod J.* 2019; 52(3): 343-51.

95. Grande NM, Ahmed HMA, Cohen S, Bukiet F, et al. Current assessment of reciprocation in endodontic preparation: A comprehensive review - Part I: Historic perspectives and current applications. *J Endod.* 2015; 41(11): 1778-83.
96. Tinoco JM, De-Deus G, Tinoco EM, Saavedra F, et al. Apical extrusion of bacteria when using reciprocating single-file and rotary multifile instrumentation systems. *Int Endod J.* 2014; 47(6): 560-6.
97. Zupanc J, Vahdat-Pajouh N, Schäfer E. New thermomechanically treated NiTi alloys - a review. *Int Endod J.* 2018; 51(10): 1088-103.
98. Goo H-J, Kwak SW, Ha J-H, Pedullà E, et al. Mechanical properties of various heat-treated nickel-titanium rotary instruments. *J Endod.* 2017; 43(11): 1872-7.
99. Ha JH, De-Deus G, Versluis A, Kwak SW, et al. Safe pseudo-elastic limit range under torsional loading with Reciproc Blue. *Int Endod J.* 2019; 52(2): 244-9.
100. You S-Y, Kim H-C, Bae K-S, Baek S-H, et al. Shaping ability of reciprocating motion in curved root canals: A comparative study with micro-computed tomography. *J Endod.* 2011; 37(9): 1296-300.
101. Varela-Patino P, Ibanez-Parraga A, Rivas-Mundina B, Cantatore G, et al. Alternating versus continuous rotation: A comparative study of the effect on instrument life. *J Endod.* 2010; 36(1): 157-9.
102. Yared G. Canal preparation using only one Ni-Ti rotary instrument: preliminary observations. *Int Endod J.* 2008; 41(4): 339-44.
103. Gavini G, Caldeira CL, Akisue E, Candeiro GTdM, et al. Resistance to flexural fatigue of reciproc R25 files under continuous rotation and reciprocating movement. *J Endod.* 2012; 38(5): 684-7.
104. Perez-Higueras JJ, Arias A, de la Macorra JC, Peters OA. Differences in cyclic fatigue resistance between ProTaper Next and ProTaper Universal instruments at different levels. *sJ Endod.* 2014; 40(9): 1477-81.
105. Paqué F, Zehnder M, De-Deus G. Microtomography-based comparison of reciprocating single-file F2 ProTaper technique versus rotary full sequence. *J Endod.* 2011; 37(10): 1394-7.
106. Espir CG, Nascimento-Mendes CA, Guerreiro-Tanomaru JM, Freire LG, et al. Counterclockwise or clockwise reciprocating motion for oval root canal preparation: A micro-CT analysis. *Int Endod J.* 2018; 51(5): 541-8.
107. Siddique R, Nivedhitha MS. Effectiveness of rotary and reciprocating systems on microbial reduction: A systematic review. *J Conserv Dent.* 2019; 22(2): 114-22.
108. Karatas E, Arslan H, Kırıcı D, Alsancak M, Çapar ID. Quantitative evaluation of apically extruded debris with Twisted File Adaptive instruments in straight root canals: Reciprocation with different angles, adaptive motion and continuous rotation. *Int Endod J.* 2016; 49(4): 382-5.
109. Arslan H, Doganay E, Alsancak M, Çapar ID, Karatas E, Gündüz HA. Comparison of apically extruded debris after root canal instrumentation using Reciproc instruments with various kinematics. *Int Endod J.* 2016; 49(3): 307-10.
110. Paqué F, Boessler C, Zehnder M. Accumulated hard tissue debris levels in mesial roots of mandibular molars after sequential irrigation steps. *Int Endod J.* 2011; 44(2).
111. Gizem Demiray K, Ahmet G, Bülent A, Güven K. Comparison of the smear layer- and debris-removal abilities and the effects on dentinal microhardness of 5% and 17% EDTA solutions used as final irrigants: In vitro study. *Acta Odontol Turc.* 2016; 33(2): 63-8.
112. Kim H-J, Park S-J, Park S-H, Hwang Y-C, et al. Efficacy of flowable gel-type EDTA at removing the smear layer and inorganic debris under manual dynamic activation. *J Endod.* 2013; 39(7): 910-4.
113. Gupta J, Nikhil V, Jha P. Corelation between machine-assisted endodontic irrigant agitation and apical extrusion of debris and irrigant: A laboratory study. *Sci World J.* 2014; 2014: 346184. DOI: 10.1155/2014/346184.
114. Baker NA, Eleazer PD, Averbach RE, Seltzer SP. Scanning electron microscopic study of the efficacy of various irrigating solutions. *J Endod.* 1975; 1(4): 127-35.
115. Hinrichs RE, Walker WA, 3rd, Schindler WG. A comparison of amounts of apically extruded debris using handpiece-driven nickel-titanium instrument systems. *J Endod.* 1998; 24(2): 102-6.
116. Ferraz CCR, Gomes NV, Gomes BPFA, Zaia AA, et al. Apical extrusion of debris and irrigants using two hand and three engine-driven instrumentation techniques. *Int Endod J.* 2001; 34(5): 354-8.
117. Myers GL, Montgomery S. A comparison of weights of debris extruded apically by conventional filing and canal master techniques. *J Endod.* 1991; 17(6): 275-9.
118. Johnson BR, Remeikis NA. Effective shelf-life of prepared sodium hypochlorite solution. *J Endod.* 1993; 19(1): 40-3.
119. Grossman LI, Meiman BW. Solution of pulp tissue by chemical agents. *J Am Dent Assoc.* 1941; 28(2): 223-5.
120. Buck RA, Eleazer PD, Staat RH, Scheetz JP. Effectiveness of three endodontic irrigants at various tubular depths in human dentin. *J Endod.* 2001; 27(3): 206-8.
121. Zehnder M. Root canal irrigants. *J Endod.* 2006; 32(5): 389-98.
122. Violich D, Chandler N. The smear layer in endodontics - a review. *Int Endod J.* 2010; 43: 2-15.
123. Putzer P, Hoy L, Günay H. Highly concentrated EDTA gel improves cleaning efficiency of root canal preparation *in vitro*. *Clin Oral Investig.* 2008; 12(4): 319-24.
124. Cruz A, Vera J, Gascón G, Palafox-Sánchez CA, et al. Debris remaining in the apical third of root canals after chemo-mechanical preparation by using sodium hypochlorite and glyde: An *in vivo* study. *J Endod.* 2014; 40(9): 1419-23.
125. De-Deus G, Marins J, de Almeida Neves A, Reis C, et al. Assessing accumulated hard-tissue debris using micro-computed tomography and free software for image processing and analysis. *J Endod.* 2014; 40(2): 271-6.

What's new for the clinician?

- Excerpts from and summaries of recently published papers

SADJ February 2021, Vol. 76 No. 1 p37 - p40

Compiled and edited by V Yengopal

1. The effect of pre-anaesthesia with a needle-free system versus topical anaesthesia on injection pain of the inferior alveolar nerve block: a randomized clinical trial

S Yıldırım, M Tokuç, MN Aydın. The effect of pre-anaesthesia with a needle-free system versus topical anaesthesia on injection pain of the inferior alveolar nerve block: a randomized clinical trial. Clin Oral Invest. 2020; 24: 4355-61.

INTRODUCTION

A common pain control method used in children and adults is the application of a local anaesthesia prior to treatment. Among local anaesthesia methods, the inferior alveolar nerve block (IANB) is frequently used to ensure pain control prior to procedures such as restoration of mandibular primary and permanent molar teeth, endodontic treatments, and surgical interventions.¹

The IANB method consists of three stages of administration of the anaesthetic solution: inserting the needle through the alveolar mucosa, placing the needle into the target location, and finally, depositing the anaesthetic solution at the target location.

A number of studies have shown that techniques that allow for a painless method of inserting the needle through the alveolar mucosa often contributes to much more relaxed child who is less anxious and displays a more positive dental behaviour throughout the dental procedure.

Various methods have been investigated for preventing the pain of an IANB, such as applying topical anesthetics prior to the injection, warming or buffering the solution prior to administration, using a computer-controlled anaesthesia delivery system such as the Wand system, and employing modern devices, like DentalVibe that uses vibration and the two-stage injection technique.¹

Comfort-in™ (Korea), one of the more recent dental devices, was developed to administer local anaesthesia using a needle-free injection method. The developers of this system claim that it is an easy to use, virtually pain-free, needle-free jet injector system, which eliminates the fear, pain, and danger of needles from the injection process.

Common uses include insulin injections, use in dental clinics, vitamin injections such as methyl B12, men who have erectile dysfunction (ED), hormone therapy, growth hormones, IVF treatments, allergy shots, etc. As much as 25% of adults and up to 75% of children have needle-phobia. Needle phobia contributes to situations where adult patients delay or forego treatment altogether, and physicians and other professionals such as dentists are left in an awkward position of having to cause pain.

The Comfort-in™ system is a patented device using the "liquid jet" system to inject the anaesthetic solution rapidly (one-third of a second) from a 0.15 mm hole with high pressure. Yıldırım and colleagues (2020) reported on a trial that sought to compare the effectiveness of pain control between a needle-free system and topical anaesthesia applied prior to inferior alveolar nerve block (IANB).

MATERIALS AND METHODS

This was a randomized, controlled cross-over clinical trial with 60 children, aged 6–12 years. Healthy, cooperative (exhibiting "positive" and "absolutely positive" behaviour on the Frankl Behaviour Scale (FBS)) children requiring IANB for dental treatments (restorative and endodontic procedures) on their bilateral mandibular primary or permanent molars were included in the study.

Veerasamy Yengopal: BChD, BScHons, MChD, PhD, Community Dentistry Department, School of Oral Health Sciences, University of Witwatersrand, Medical School, no. 7 York Road, Parktown 2193, South Africa.
ORCID Number: 0000-0003-4284-3367
Email: veerasamy.yengopal@wits.ac.za

All patients had previous experience with infiltration anaesthesia but not IANB. Based on medical history, children under medication or who were found to have a chronic disease or history of allergy were excluded.

Dental treatments with IANB were administered to bilateral mandibular molars of each patient in two separate sessions at 1-week intervals. Before IANB, topical anaesthesia was applied in one session and needle-free injection was applied in the other session as pre-anaesthesia.

The first pre-anaesthesia method was randomly assigned to each patient with a computer-assisted program. The operator was asked to select the side to do the first treatment before the researcher revealed the pre-anaesthesia method to be applied, to avoid possible operator bias. In this study, all anaesthesia procedures and dental treatments were performed by the same operator.

Before initiating treatment, each patient underwent age-appropriate behaviour management. All dental equipment was introduced using the “tell-show-do” technique. Injection was described to patients using reframing methods (for instance, using euphemistic phrases such as “putting the tooth to sleep”).

One hundred twenty IANB injections were performed in total. Patients were divided into two groups, according to the two pre-anaesthesia procedures, prior to IANB.

- **Topical anaesthesia group (TA):** The IANB injection site was dried, and topical anaesthetic spray containing 10% lidocaine (Xylocaine) was applied with a cotton pellet for 60s.
- **Comfort-in™ injection system group (CIS):** Before application, patients were given a demonstration of the popping sound produced by the device during the injection. The Comfort-in™ system was prepared according to the manufacturer’s recommendation, and 0.1 mL of 4% articaine hydrochloride with 1/100,000 epinephrine (Ultracaine) was drawn into the needle-free syringe using filling adapters.

The device was placed at the IANB injection site, and the anaesthetic solution was injected into the mucosa by pressing the button on the back of the device. Subjective and objective pain assessments were performed during Comfort-in™ application.

Waiting 5 min after the pre-anaesthesia procedure, IANB injections were administered to each patient with a 27-gauge dental needle using a standardized approach. The effectiveness of pre-anaesthesia methods on injection pain during IANB was assessed subjectively and objectively in the “needle insertion” and “solution deposition” phases.

The Wong-Baker PRS was used for subjective assessment. The pain level of patients is judged according to face images ranging from smiling to crying with ratings between 0 and 5: 0 signifies “no hurt” and 5 indicates “hurts worst”.

The Face, Legs, Activity, Cry, Consolability (FLACC) scale was used for objective assessment. This scale consists

of five parameters - facial expression, legs, activity, crying, and consolability. The rater scores each parameter from 0 to 2 points by observing the patient. Total scores range from 0 to 10. A score of 0 means “no pain,” scores between 1 and 3 mean “mild pain,” 4 to 6 indicate a “medium level of pain and discomfort,” and scores of 7 and above indicate “severe pain and discomfort”.

At the end of the second session, after IANB injection, patients were asked which pre-anaesthesia method they preferred, and their answers were recorded.

RESULTS

60 children - 33 girls (55%) and 27 boys (45%) - who were 6 - 12 years of age (8.37 ± 0.26) were included in this study. On both scales, significantly higher pain ratings were observed in the **Topical anaesthesia group (TA)** group during needle insertion ($p < 0.01$) and solution deposition ($p < 0.01$) when compared to the **Comfort-in™ injection system group (CIS)** group.

On the FLACC scale, the number of “no pain” ratings was higher in the CIS group than in the TA group for both needle insertion (CIS, 36; TA, 1) and solution deposition (CIS, 32; TA, 1). In contrast, the number of “severe pain” ratings was lower in the CIS group than in the TA group for needle insertion (CIS, 1; TA, 2) and solution deposition (CIS, 1; TA, 5).

Similarly, according to the Wong-Baker PRS, the number of “no hurt” ratings was higher in the CIS group than in the TA group for needle insertion (CIS, 27; TA, 2) and solution deposition (CIS, 29; TA, 3). The number of “hurts worse” ratings was lower in the CIS group than in the TA group for needle insertion (CIS, 1; TA, 2) and the same for solution deposition (CIS, 1; TA, 1).

There was no statistically significant difference in terms of patient preference. While 50% ($n = 30$) of the children preferred CIS, the remaining half ($n = 30$) preferred TA. No significant gender difference was found in patient preference. Seventeen (56.7%) of 33 girls preferred the use of the CIS before IANB, while 13 (43.3%) of 27 boys chose the CIS.

There was a statistically significant association between age and patient preference ($p < 0.001$). A negative association was found between age and scale ratings, except in the TA group in which no association was found between age and PRS ratings both for needle insertion and for solution deposition phases ($p > 0.05$).

CONCLUSIONS

The researchers concluded that in both the objective and subjective pain assessments, the needle-free system reduced the injection pain of undergoing IANB. Both methods (CIS and TA) were equally preferred by the patients.

Implications of practice

Before using the results of this trial, clinicians should note the inclusion criteria used (Healthy, cooperative (exhibiting “positive” and “absolutely positive” behaviour on the Frankl

Behaviour Scale (FBS)) children requiring IANB) and also note that patients had no preference in terms of TA or the CIS.

Reference

1. Yıldırım S, Tokuç M, Aydın MN. The effect of pre-anaesthesia with a needle-free system versus topical anaesthesia on injection pain of the inferior alveolar nerve block: a randomized clinical trial. *Clin Oral Invest.* 2020; 24: 4355-61.

2. Comparison of two vasoconstrictors on glycemic levels in diabetic patients

D Meneses-Santos, KS Amorim, ACGC Dantas, et al. Comparison of two vasoconstrictors on glycemic levels in diabetic patients. *Clin Oral Invest.* 2020; 24; 4591-6.

INTRODUCTION

Diabetes mellitus (DM) is common among patients attending for dental treatment. The most common forms of DM are Type 1 and Type 2. Type 1 DM (DM1) is an autoimmune disease destroying pancreatic β cells, leading to poor insulin production.¹ Type 2 DM (DM2) has multifactorial causes, it is usually associated with obesity, hypertension, and dyslipidemia, and affects both β cell function and insulin tissue sensitivity.

Fear and anxiety are common factors associated with dental care. The dental anaesthesia, an essential procedure for performing dental treatment, may generate pain; it is also associated with anxiety, odontophobia, and can lead to changes in corticosteroid secretion and sympathomimetic hormones, which can act as hyperglycemic agents. In diabetics with altered insulin metabolism, stress may be a factor to potentiate hyperglycemia. Thus, oral surgery requires special care, including stress control and the use of safe and effective anaesthetic solutions.

Some authors have reported an increase in blood glucose levels after the administration of local anesthetics containing adrenaline as vasoconstrictor.¹ The recommended anesthetics in these patients may be 3% mepivacaine without vasoconstrictor or 3% prilocaine with 0.03 IU/mL felypressin.¹

Felypressin is indicated in non-controlled diabetic patients because it does not activate α - nor β -adrenergic receptors.¹ However, it presents some disadvantages, such as deficient hemostasis control and short pulpal anaesthesia.

Meneses-Santos and colleagues (2020) reported on a trial that sought to evaluate glycemic levels in controlled diabetic patients before, during, and after extraction using 2% lidocaine with 1:100,000 epinephrine and 3% prilocaine with 0.03 IU/mL felypressin.

MATERIALS AND METHODS

This was a double-blind parallel controlled clinical trial which sought to evaluate changes in physical parameters and glycemic levels in diabetic patients undergoing two anaesthetic protocols during tooth extractions. All patients

were diabetic controlled by oral medication (oral hypoglycemic agents and insulin). Inclusion criteria were patients over 18 years of age, DM controlled by medication, requiring a tooth extraction in the mandible, with an indication of the intra-alveolar technique.

Exclusion criteria were any significant medical condition (besides DM), alcoholic individuals, patients on drugs that affect the central nervous systems, patients who reported the use of drugs that might interfere with pain sensitivity within 15 days prior to the surgery, and those who reported pregnancy, lactation, odontophobia, or hypersensitivity to local anesthetics or non-steroidal anti-inflammatory drugs (NSAIDs).

The participants were randomly divided into two groups: Lido/Epi group (20 patients), who were anesthetized with 2% lidocaine with 1:100,000 epinephrine (Alphacaine®), and Prilo/Fely group (20 patients), who were anesthetized with 3% prilocaine with 0.03 IU/mL felypressin (Prilonest®).

The present study was conducted in three phases. In phase I, the degree of anxiety was assessed in all participants before the surgical procedure by applying the Corah Dental Anxiety Scale. Subsequently, the basal physical parameters, such as systolic (SBP) and diastolic (DBP) blood pressure, heart rate (HR), blood oxygen saturation (SpO₂), and glycemic levels by capillarity were evaluated. Glycemic levels were determined by using a glucometer (Accu-Chek® Active).

In phase II, the baseline physical parameters were measured and in both groups, patients received a *Passiflora incarnata* capsule (500 mg orally, 1 h before the start of the surgical procedure) for anxiety control. The physical parameters were measured 30 min after the capsule administration. At the time of surgery, 3.6 mL of lido/epi or prilo/fely was administered by an inferior and buccal alveolar nerve block. At this point, the timer was triggered up to 60 min after the anaesthesia. Physical parameters were measured at different surgical moments: during incision, during tooth removal, during suture, and 30 and 60 min after anaesthesia. Furthermore, the investigator and operator responsible for the surgery evaluated the degree of

anxiety, both of them did answer the same questionnaire at the end of each surgical procedure. In the postoperative period, sodium dipyrone 500mg every 6h for 48h was prescribed.

In phase III, performed 8 days after the tooth extraction and during suture removal, the side effects resulting from the medication used in this study were evaluated using a questionnaire.

RESULTS

Forty participants were included in this study. No differences were observed between the study groups in age, weight, gender, time of surgery gender, surgery sides, and the initial anxiety level. All surgical procedures were completed before 30min. The majority of the sample was low-anxiety level patients.

The use of lido/epi induced a significant increase in systolic blood pressure (SBP) during the “incision” period in comparing to “basal,” “anaesthesia,” and “60 min after anaesthesia” periods. The last period showed lower SBP than that in the “tooth removal” period. No differences were found in the other periods.

Prilo/fely caused increased SBP during “suture” when compared with “basal,” “30 min after anaesthesia,” and “60 min after anaesthesia” periods. Markedly, when lidocaine was used, SBP peaks greater than 160mmHg were observed in eight (40%) patients during the incision, six (30%) during tooth removal, five (25%) during suturing, four (20%) after 30 min of anaesthesia, and three (15%) at the end of the procedure. None of the patients presented these peaks at the baseline.

When prilo/fely was used, these peaks were observed in two (10%) patients during the baseline, eight (40%) during the incision, nine (45%) during tooth removal, nine (45%) during suturing, six (30%) after 30 min of anaesthesia, and three (15%) at the end of the procedure.

No differences among the periods were observed considering SpO₂ for both lido/epi ($p=0.94$) and prilo/fely ($p=0.91$). Levels of HR did not show differences ($p>0.05$) between basal values and those obtained in other periods for both local anesthetics despite the sporadic fluctuations.

There was a marked reduction in blood glucose caused by Lido/Epi, from 30 min of *P. incarnata* administration until the last period when compared to the baseline value. Although less pronounced, prilo/fely also significantly decreased glucose, starting at the “tooth removal” period until the last period when compared to the baseline.

Six episodes of increased blood glucose above the initial measurements (5.0% of 120 measurements) were observed when lido/epi was used, but prilo/fely caused 28 (23.3%) episodes.

In general, no improvement or worsening was observed between the initial anxiety and the anxiety reported on the day of surgery. Besides that, no difference between the perception of the operator and researcher was seen about the anxiety declared by the patient.

CONCLUSIONS

The researchers concluded that 3.6 ml of lidocaine 2% plus 1:100,000 epinephrine or prilocaine 3% plus felypressin presented safe for controlled diabetic patients. The use of lidocaine associated with epinephrine did not increase glycemic levels, but led to a decrease over time when associated with an anxiety reduction protocol, offering some advantage over prilocaine plus felypressin for diabetic patients.

Implications for practice

Diabetes is a major public health problem in our communities and the safe use of local anaesthesia for these patients contributes to maintenance of healthy glycaemic levels during dental treatment.

Reference

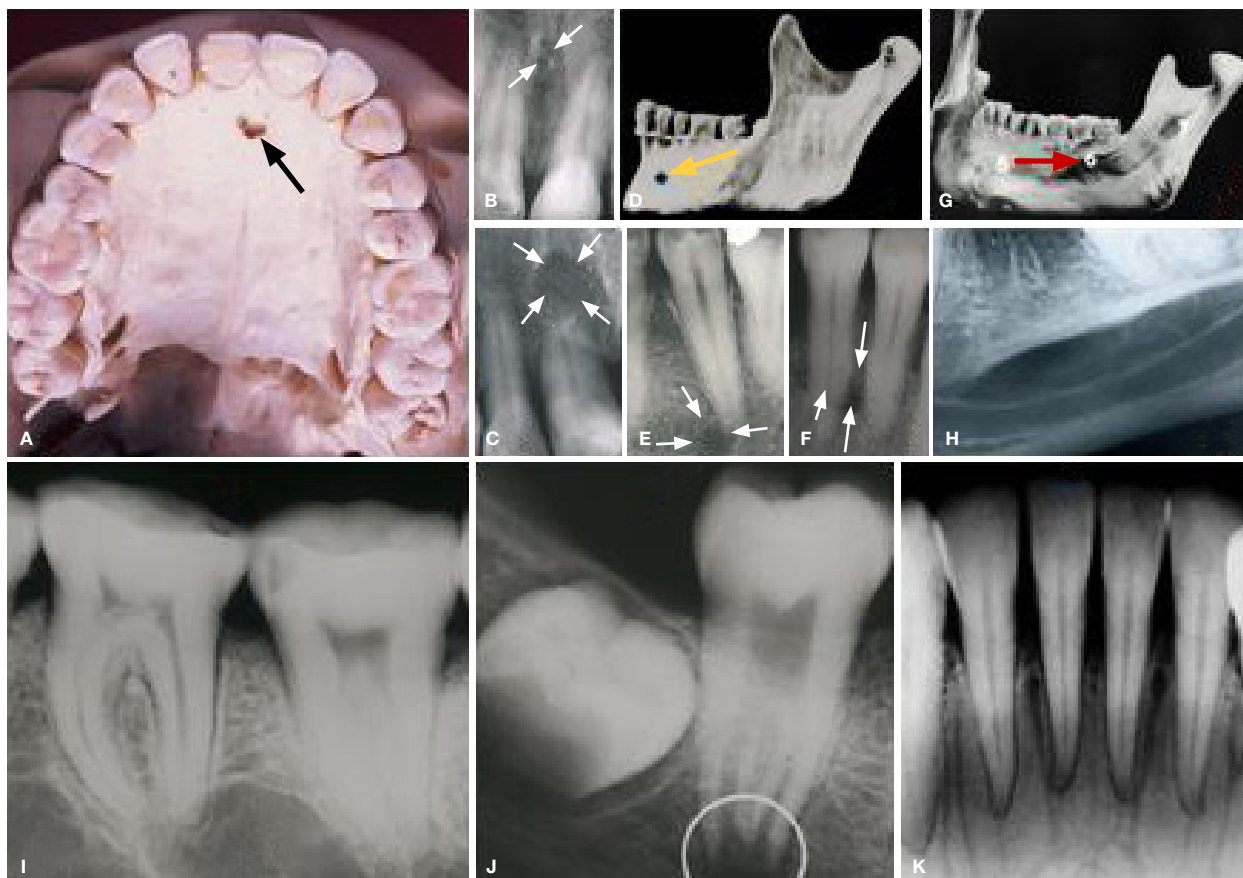
1. Meneses-Santos D, Amorim KS, Dantas ACGC, et al. Comparison of two vasoconstrictors on glycemic levels in diabetic patients. *Clin Oral Invest.* 2020; 24; 4591-6.

Maxillofacial Radiology 187

SADJ February 2021, Vol. 76 No. 1 p41

CJ Nortjé

Below are six normal anatomical landmarks (ABC), (DEF), (GH), (I), (J) and (K) which could due to faulty angulation or lack of knowledge be diagnosed as underlying pathology or traumatic injury. Identify the anatomical landmarks illustrated and discuss the reason(s) why a faulty diagnosis could be made.



INTERPRETATION

Figures A, B, C, are radiographic images of the incisive foramen, which is an opening in the bone of the oral hard palate immediately behind the incisor teeth. In the incisive foramen the orifices of two lateral canals are visible; they are named the foramina of Stenson and additional canals are present in the middle line; they are termed the foramina of Scarpa (Fig. A & B). A terminal branch of the maxillary nerve, the nasopalatine nerve, runs from the nasal cavity, through the incisive canal and supplies the tissues of the anterior part of the hard palate. Figure C shows a radiolucency at the apex of the 11 which could be diagnosed as an apical lesion instead of the incisive foramen due to a faulty angulation used during the x-ray examination. Figures D, E, show the normal position (yellow arrow) of the mental foramen through which the nerve and blood vessels emerge is seen as a round or oval radiolucency and but due to a faulty angulation during the taking of the X-ray one observe the abnormal position of the mental

foramen (Fig. F) suggesting the possible presence of a periodontal lesion. Figure G shows the mylohyoid ridge (red arrow) and submandibular fossa. According to the literature a prominent mylohyoid ridge and deep mandibular fossa may produce an image that may be mistaken for that of tumour or cyst (Fig. H). Fig. I shows two large radiolucency's suggestive of underlying pathology, however it is large marrow spaces presenting in the premolar and molar regions. Figure J is an example of a dentin papilla that is superimposed on the image of the mandibular canal producing a marked radiolucency suggestive of a periapical lesion which often occurs with the development of second and third molar teeth. Figure K shows multiple well demarcated vertical radiolucent lines suggestive of multiple fractures but the radiolucent lines lead directly to the apical foramina suggestive of interdental nutrient canals which are mostly observed in the edentulous regions. These canals contain blood vessels and nerves that supply the teeth and gingiva.

Christoffel J Nortjé: BChD, PhD, ABOMR, DSc. Faculty of Dentistry, University of the Western Cape.
ORCID Number: 0000-0002-9717-5514
Email: cnortje@uwc.ac.za

References

1. Stafne EC, Gibilisco JA. Oral Roentgenographic Diagnosis, 4th Ed. Saunders. Philadelphia, London, Toronto. 1975; 1-7.

Mandatory COVID-19 vaccination for oral health professionals (OHPs) - Ethical appraisal

SADJ February 2021, Vol. 76 No. 1 p42 - p45

LM Mtolo¹, PD Motloba², NH Wood³

ABSTRACT

The recently detected South African variant, Covid-19, 501Y.V2 is more transmissible, though not virulent as the initial strain.¹ The morbidity and mortality rates due to this variant have risen exponentially, putting huge pressure on the healthcare system, locally and globally.

As a consequence the South African government imposed hard lockdown measures (level 3) as a means to curb the pandemic. Governments around the world are scrambling to obtain and roll-out Covid-19 vaccination programs to save lives and livelihoods. Most developed countries have initiated inoculations, amid widespread misinformation and hesitancy.

Literature indicate that healthcare professionals (HCPs) are generally complacent and hesitant about vaccination. The COVID-19 uptake is likely to be suboptimal among HCPs and the general populations. The voluntary immunization program will commence in February 2021, and the Healthcare professionals will be among the first to be vaccinated.

It remains to be seen if this cohort will achieve the desired vaccinations rates. Failure for this influential group to vaccinate could derail the program and lead to failure to achieve herd immunity. In the face of emerging vaccine hesitancy among HCPs, should oral health professionals be compelled to vaccinate? Will any refusal by OHPs to be immunized be morally justified?

Oral health professionals in this context of this paper, represent all oral health professionals involved in the management dental patients.

Author affiliations:

1. **Thembelihle M Mtolo:** *BTech (DT)(TUT)*, Senior Dental Technologist, Dental Laboratory, Sefako Makgatho Health Sciences University, South Africa.
2. **Pagollang D Motloba:** *BDS (Medunsa), MPH (Epidemiology) (Tulane)*, Head, Department of Community Dentistry, School of Oral Health Sciences, Sefako Makgatho Health Sciences University.
ORCID Number: 0000-0003-1379-7576
3. **Neil H Wood:** Department of Periodontology and Oral Medicine, School of Oral Health Sciences, Sefako Makgatho Health Sciences University.
ORCID Number: 0000-0001-8950-7999

Corresponding author: Pagollang D Motloba

Department of Community Dentistry, School of Oral Health Sciences, Sefako Makgatho Health Sciences University.
Email: pagollang.motloba@smu.ac.za

Author contributions:

1. **Thembelihle M Mtolo:** Primary author - 30%
2. **Pagollang D Motloba:** Second author - 50%
3. **Neil H Wood:** Third author - 20%

No singular ethical framework is held as sufficient to resolve these questions. This paper interrogates aspect of clinical ethics, including the Hippocratic Oath, principlism, public health ethics (Utilitarianism) and Kantian deontology, to tackle the questions raised. We conclude that OHPs have a moral duty to be vaccinated against Covid-19.

INTRODUCTION

South Africa's first batch of one million Covid-19 vaccines arrived in the country on Monday (1 February). Despite logistical challenges and the complexities of rolling out the vaccination efforts, it remains to be seen whether uptake will be commensurate to the effort and gravity of the pandemic. Frontline healthcare professionals will be among the first persons to receive the vaccine in South Africa. Unfortunately not all healthcare professionals want to be the first in line. Vaccine hesitancy could negatively impact the plan to build herd immunity by inoculating 67% (40 million) of the South African population.²

The acceptability of COVID-19 vaccines by healthcare professionals (HCPs) is critical to improve vaccination uptake by the public.³ The attitudes of health professionals about vaccines are an important determinant of the likelihood of patient's behavior regarding vaccination. This means that patients are more inclined to accept vaccination if their healthcare providers recommend it.⁴

Regrettably the literature indicates that healthcare professional's willingness to vaccinate is not significantly different from that of the general population.⁵ These statistics raise critical questions about the healthcare professional's intention to vaccinate, and the causes of their hesitancy. The low vaccination rates by healthcare workers, and by extension the population, represents the most serious global threat during this pandemic.

We ask if healthcare professionals should be obligated to vaccinate, more so that COVID-19 vaccination is currently not mandatory in South Africa. Can refusal of these frontline workers to be immunized be justified? More specifically, are OHPs, who are at increased risk of contracting COVID-19, obligated to vaccinate?

Overview of current Covid-19 vaccines

The extraordinary speed at which Covid-19 vaccines are developed is unprecedented and remarkable.⁶ Since April

2020, over 115 vaccines were candidates of rapid development and clinical trials around the world.⁷ Very few of these vaccines have achieved clinically significant efficacy levels for mass inoculation.

Currently immunization is ongoing using Pfizer®-BioNTech COVID-19, Moderna® COVID-19 and AstraZeneca® Covid-19 vaccines.⁸ Pfizer® and Moderna® vaccines use mRNA technology and require subzero refrigeration. A two-dose regimen of Pfizer® BNT162b2 vaccine confers 95% protection against Covid-19 in persons 16 years and older.⁹

The efficacy of the Moderna® vaccine (mRNA-1273) in preventing symptomatic COVID-19 disease is recorded to be 94.1%.¹⁰ The AstraZeneca® vaccine uses adenovirus vectored technology, and is storable at higher temperatures (2.2 - 7.8)°C. This makes this vaccine easier and cheaper to distribute globally despite its lower efficacy (70%).

Russian vaccines, the Sputnik V® (the first vaccine to be developed in the world) and EpiVacCorona® have attracted criticism from regulatory agencies leading to limited uptake globally.¹¹ Despite the controversies surrounding the clinical trials, these vaccines showed 91.45% and 95% efficacy.¹² These four vaccines seem to prevent the Covid-19 infections, however like all other vaccines, the risk of anaphylaxis remain a serious concern.

Currently many candidate vaccines are subject of clinical trials and could soon be rolled out, including: the Ad5-nCoV13 and the Corona Vac¹⁴ (China); the NVX-CoV-2373 vaccine¹⁵ (by Novavax®, USA); the Ad26.COV2.S¹⁶ (Johnson and Johnson®, USA and Netherlands).

As the vaccine race continues, a “new” normal is imminent, but some countries are set to get there faster than others.

Side-effects of COVID-19 vaccines

Covid-19 virus has unstable genome, resulting in numerous and rapid mutations.^{14,17} This could mean that the efficacy of the vaccines may differ depending on the strain and country of production.¹⁸

Therefore the reported efficacies might not be conferred and sustained everywhere in the world. Conceivably, there might be a need for yearly vaccination to sustain the protection or booster immunity against the virus.¹⁹

Similarly, the side effects will be variable, depending on the vaccines used. The reported side-effects of Covid-19 vaccines are based on data from phase III clinical trials. Patients who participated in these trials presented commonly with pain from the injection site, fatigue, headache, muscle and joint pains, chills and fever.²⁰

These symptoms are not unique to Covid-19 vaccines and resolve rapidly.²¹ Few adverse events have been reported, such as lymphadenopathy, paralysis and anaphylaxis.²² The phase IV trial period provides an opportunity for the medical community to understand the long term effects and adverse events of the Covid-19 vaccines and how to manage them.

Dental practice in the time of Covid-19

Very few OHPs are reported to have contracted SARS-CoV-2 in the dental practices. This is largely due to adherence to strict prevention protocols, including wearing of mask, sanitization, social distancing and ventilation.²³ Additionally, most OHPs restricted their practices to management of emergency cases. However, oral health professionals work in close proximity with the patients, making the risk of contracting Covid-19, a real possibility - and possibly a matter of ‘when’, not ‘if’.²⁴ SARS-CoV-2 is present in saliva, droplets and aerosols which contaminate surfaces and objects in the dental practice and the virus can remain viable for up to 9 days.

The emergence of the new and highly transmissible variant presents a grave threat to the sustainability of many dental practices, unless herd immunity is achieved and the “new” normality is restored.²⁵

Is there an ethical duty for OHPs to vaccinate, or not?

a). Hippocratic Oath and Georgetown Mantra (Principlism)

When a dentist accepts, without coercion, the responsibility to care for any patient, their individual rights assume a subservient position to the dentist-patient relationship. Based on their duty of care towards patients, they are obligated to act professionally and responsibly and protect the best interests of their patients. According to the Hippocratic Oath and Georgetown Mantra (Principlism): i) the primary obligation of OHPs is not to harm their patient “primum non nocere”, or non-maleficence; (ii) promotion of patient’s wellbeing or beneficence; (iii) respect patient’s expectations and preferences or autonomy; and (iv) not to prejudice patients in any way (justice).

The argument for mandatory vaccination of OHPs is grounded on the following premises:

1. That an unvaccinated OHPs should not treat patients, as doing so poses huge risk to patient’s health, including the risk of death. OHPs will be failing to protect their patients from harm; and will be engaging in unethical practice of non-maleficence. Patients are vulnerable and have to be protected from any form of harm including from their OHPs. OHPs should at all times, engage in activities that promote the wellbeing of their patients.
2. By participating in vaccination programs and ongoing phase IV surveillance trial, OHPs will be making an immense and informed contribution to common good. First, OHPs are best placed to understand their medical status and vaccines-related complications. This will enrich the quality in reporting and of data generated from the post-marketing trials.

Second, medical interventions have side effects, and OHPs’ refusal to vaccinate themselves would be a failure to acknowledge this fundamental clinical reality and medical phenomenon. It would be hypocritical of OHPs not to be vaccinated, when the medicines or procedures they prescribe to unsuspecting patients

may have unknown long term side-effects. OHPs are obligated to implement medical interventions that are supported by “some” evidence, including the Covid-19 vaccine.

Third, a paucity of data on the long-term effects of Covid-19 is likely to contribute to “omission bias”.²⁶ This is the tendency to favour inaction (no vaccination) than commission (inoculation) when either can cause harm. The benefit (utility, reciprocity, group beneficence) to harm ratio is greater for oral health professionals to persuade OHPs to vaccinate. It is hence unjustifiable for a OHPs to refuse to vaccinate, even when it feels safer.

Fourth, by choosing to immunize, OHPs will contribute to improved patients’ attitudes and intention towards immunization. Patients are likely to emulate and take advice from their OHPs. This could lead to increased uptake and eventually realization of the program goal (herd immunity).

Fifth, the generalised refusal by OHPs to vaccinate could have a catastrophic effect on the management of the pandemic. Notwithstanding the widespread misinformation and falsehoods on the vaccines, the premises above offer cogent arguments for mandatory vaccination of OHPs. It would be prudent for dental associations to advocate for greater involvement of OHPs in the vaccination program. Dental practices should be readied as immunizations sites, and OHPs trained to immunize patients.

b). Bentham’s Utilitarianism

The Utilitarian ethical frameworks replace the individual ends with public concerns. Contrary to the Hippocratic Oath and Principlism, Bentham asserts that the objective of any action is to achieve maximum utility. This means consequences of an action is the ultimate basis for any judgment about the rightness or wrongness of that conduct. Therefore the optimization of public prevention effort (e.g. intensification of vaccination program) is utilitarian for as long it prevents public transmission of the disease. Partif refers to this principle of utility maximization as the Group Beneficence Principle.²⁷

Like communitarian approach, individuals have moral obligation to benefit the collective. It is hence expected that an individual’s contribution and effort, will lead to positive outcomes for the collective.²⁸ The same principle has been applied to healthcare facilities, by targeting all HCPs for the benefit of the collective. For example, the introduction of mandatory vaccination in dental practices as a condition of employment would result in Group Beneficence.

This effort should result in many HCPs immunised, leading to “greatest happiness or benefit for the greatest number”. We argue that mandatory immunization policies support the professional duty to protect others including patients. This policy infringes the dentist’s agency or autonomy, and violates the law. To implement such policies, one has to appeal to supererogation a plea to clinician to go beyond their call of duty.

Despite any associated ethical and moral contradictions, the implementation of mandatory vaccination has significantly reduced risks of diseases in healthcare institutions.²⁹ It is therefore incumbent on policy makers to design programs that incentivise and encourage HCPs to vaccinate.³⁰ According to Bentham’s utilitarian morality, OHPs may not refuse to immunize. The consequences of such actions are far worse than the inoculation itself.

c). Kantian Deontology

Kantian deontology, establishes that acting according to “duty” and for “duty’s sake” is a categorical imperative.³¹ This means an individual must act in accordance to maxim so that it becomes universal law (generalization test).³²

To evaluate the morality of an act according to Kant’s universal law, we ask - what if everybody acted in this way? What if OHPs everywhere refused vaccination, including for their close relations? Generalised refusal to vaccinate would certainly hinder the realization of herd immunity, which is not moral according to Kant.

Herd immunity might still be achieved if few OHPs don’t vaccinate. However, the refusal of one dentist is one too many, and could lead to a “slippery slope” from the vaccination program might not recover. It is irrational for OHPs to refuse as a collective to contribute to building of herd immunity and protection other human being. It cannot be willed that such an action be universal law.

With regards to autonomy, Kant argues that in our pursuit for “greatest good” or positive outcomes, we should “never treat humanity as a means to an end, but as an end in itself”.³³ Whatever the ultimate positive consequences are pursued, individuals should not be harmed, i.e. virtuous ends should not justify unethical means. This means that the burden on individuals to vaccinate and contribute to herd immunity, should not come at an unreasonable and unfair cost.³⁴

We ask, what cost could supersede the obligation to vaccinate? In other words what circumstances would make Covid-19 vaccination by OHPs, beyond the “call of duty” or supererogatory? Immunizations without proper medical support and consideration for cultural, religious and psychological factors could constitute high costs and conditions for exemptions. Beyond these reasons, the moral burden and grounds to reject vaccination are unjustifiable.

A dentist who receives medical support, and whose culture and religion are respected, may not have valid grounds not to vaccinate. Kant offers therefore, a strong persuasion why refusal of OHPs to vaccinate is not moral.

CONCLUSION

Voluntary vaccination programs or policies generally fail to achieve desired goals. Mandatory policies, although effective, may violate the principles of autonomy and individual rights. Amidst tensions between moral viewpoints, the evidence for mandatory vaccination remains strong.

This policy is clearly justified by the Hippocratic Oath, deontological approach, and the utilitarian standpoint.

Ethical principles offer partial justification and the appeal to individual right to choose, as grounds for OHPs to refuse vaccination is inadequate. Therefore, OHPs as frontline workers, have been prioritized to receive doses of vaccines. Without any medical contraindications, these candidates have moral duty vaccinate and contribute to attainment of herd immunity. In so doing they will continue to provide essential services to their patients.

References

- Erol A. Are the emerging SARS-COV-2 mutations friend or foe? *Immunology Letters*. 2020; 230: 63-4.
- Randolph HE, Barreiro LB. Herd Immunity: Understanding COVID-19. *Immunity*. 2020; 52(5): 737-41.
- Paterson P, Meurice F, Stanberry LR, et al. Vaccine hesitancy and healthcare providers. *Vaccine*. 2016; 34(52): 6700-6.
- Asma S, Akan H, Uysal Y, et al. Factors effecting influenza vaccination uptake among health care workers: a multi-center cross-sectional study. *BMC infectious diseases*. 2016; 16(1): 1-9.
- Kabamba Nzaji M, Kabamba Ngombe L, Ngoie Mwamba G, et al. Acceptability of Vaccination Against COVID-19 Among Healthcare Workers in the Democratic Republic of the Congo. *Pragmat Obs Res*. 2020; 11: 103-9.
- Le TT, Andreadakis Z, Kumar A, et al. The COVID-19 vaccine development landscape. *Nat Rev Drug Discov*. 2020; 19(5): 305-6.
- Corum J, Grady D, Wee S-L, et al. Coronavirus vaccine tracker. *The New York Times* 2020. Accessed at www.nytimes.com/interactive/2020/science/coronavirus-vaccine-tracker.html on 8 January 2021.
- Lipsitch M, Dean NE. Understanding COVID-19 vaccine efficacy. *Science*. 2020; 370(6518): 763-5.
- Polack FP, Thomas SJ, Kitchin N, et al. Safety and efficacy of the BNT162b2 mRNA Covid-19 vaccine. *New England Journal of Medicine*. 2020; 383(27): 2603-15.
- Baden LR, El Sahly HM, Essink B, et al. Efficacy and safety of the mRNA-1273 SARS-CoV-2 vaccine. *New England Journal of Medicine*. 2020. <https://doi.org/10.1056/NEJMoa2035-389>.
- Callaway E. Russia announces positive COVID-vaccine results from controversial trial. *Nature*. 2020. <https://doi.org/10.1038/d41586-020-03209-0>.
- De Soto JA. Evaluation of the Moderna, Pfizer/BioNtech, AstraZeneca/Oxford and Sputnik V Vaccines for COVID-19. 2020. <https://doi.org/10.31219/osf.io/e4rqu>.
- Zhu F-C, Li Y-H, Guan X-H, et al. Safety, tolerability, and immunogenicity of a recombinant adenovirus type-5 vectored COVID-19 vaccine: a dose-escalation, open-label, non-randomised, first-in-human trial. *The Lancet*. 2020. [https://doi.org/10.1016/S0140-6736\(20\)31208-3](https://doi.org/10.1016/S0140-6736(20)31208-3).
- Palacios R, Patiño EG, de Oliveira Piorelli R, et al. Double-Blind, Randomized, Placebo-Controlled Phase III Clinical Trial to Evaluate the Efficacy and Safety of treating Healthcare Professionals with the Adsorbed COVID-19 (Inactivated) Vaccine Manufactured by Sinovac-PROFISCOV: A structured summary of a study protocol for a randomised controlled trial. *Trials*. 2020; 21(1): 1-3.
- Keech C, Albert G, Cho I, et al. Phase 1-2 trial of a SARS-CoV-2 recombinant spike protein nanoparticle vaccine. *New England Journal of Medicine*. 2020; 383(24):2320-32.
- Sadoff J, Le Gars M, Shukarev G, et al. Interim Results of a Phase 1-2a Trial of Ad26.COV2.S Covid-19 Vaccine. *New England Journal of Medicine*. 2021. <https://doi.org/>.
- Knoll MD, Wonodi C. Oxford-AstraZeneca COVID-19 vaccine efficacy. *The Lancet*. <https://doi.org/>.
- Tuite AR, Zhu L, Fisman DN, et al. Alternative dose allocation strategies to increase benefits from constrained COVID-19 vaccine supply. *Annals of internal medicine*. 2021. <https://doi.org/>.
- Tegally H, Wilkinson E, Giovanetti M, et al. Emergence and rapid spread of a new severe acute respiratory syndrome-related coronavirus 2 (SARS-CoV-2) lineage with multiple spike mutations in South Africa. *medRxiv*. 2020. <https://doi.org/10.1056/NEJMoa2034201>.
- Kostoff RN, Briggs MB, Porter AL, et al. [Comment] COVID-19 vaccine safety. *International journal of molecular medicine*. 2020; 46(5):1599-1602.
- Ledford H. Oxford Covid-vaccine paper highlights lingering unknowns. *Nature*. 2020; 588: 378-9.
- Ather A, Patel B, Ruparel NB, et al. Coronavirus disease 19 (COVID-19): implications for clinical dental care. *Journal of endodontics*. 2020; 46(5): 584-95.
- Passarelli PC, Rella E, Manicone PF, et al. The impact of the COVID-19 infection in dentistry. *Experimental Biology and Medicine*. 2020; 245(11): 940-4.
- Meng L, Hua F, Bian Z. Coronavirus disease 2019 (COVID-19): emerging and future challenges for dental and oral medicine. *Journal of dental research*. 2020; 99(5): 481-7.
- Passarelli PC, Rella E, Manicone PF, Garcia-Godoy F, D'Addona A. The impact of the COVID-19 infection in dentistry. *Experimental Biology and Medicine*. 2020; 245(11): 940-4.
- Jiménez ÁV, Mesoudi A, Tehrani JJ. No evidence that omission and confirmation biases affect the perception and recall of vaccine-related information. *PloS one*. 2020; 15(3):e0228898. <https://doi.org/10.1371/journal.pone.0228898>.
- Parfit D. *Reasons and persons*: Oxford University Publishers 1984.
- Otsuka M. The paradox of group beneficence. *Philosophy & Public Affairs*. 1991: 132-49.
- Betsch C, Böhm R. Detrimental effects of introducing partial compulsory vaccination: experimental evidence. *The European Journal of Public Health*. 2016; 26(3): 378-81.
- Dubov A, Phung C. Nudges or mandates? The ethics of mandatory flu vaccination. *Vaccine*. 2015; 33(22): 2530-5.
- Wood AW. Kant, Immanuel. *International Encyclopedia of Ethics*. 2013.
- Giubilini A, Douglas T, Savulescu J. The moral obligation to be vaccinated: utilitarianism, contractualism, and collective easy rescue. *Med Health Care Philos*. 2018; 21(4): 547-60.
- Wood A. Humanity as end in itself. *Proceedings of the Eighth International Kant Congress 1995*: 301-19.
- Flanigan J. Mark Navin, Values and Vaccine Refusal: Hard Questions in Ethics, Epistemology, and Health Care. *The Journal of Value Inquiry*. 2017; 51(1):199-202.

CPD questionnaire

This edition is accredited for a total of 3 CEUs: 1 ethical plus 2 general CEUs

GENERAL

Voluntary counselling and testing for HIV in the dental setting: Knowledge, attitudes and practices of oral health care workers in eThekweni district, KwaZulu-Natal

- Choose the CORRECT statement.
With regards to the option of implementing HIV testing to the dental workplace, significant statistical differences were noted with:
 - gender
 - age group
 - profession of the oral healthcare worker
 - place of work of the oral healthcare worker (Private or Public sector)
 - years of work experience
- Choose the CORRECT statement.
With regards to the knowledge of the oral healthcare workers:
 - 37% of participants correctly indicated that HIV testing cannot be performed by obtaining saliva samples from patients
 - 30% of participants were "sure" whether HIV can be tested by obtaining urine samples from the patients
 - 89% of participants have not heard of rapid HIV testing
 - 83% of participants had not received any form of HIV counselling and testing training
- Select the CORRECT option.
Most commonly observed HIV oral lesions by oral healthcare worker participants were reportedly:
 - Periodontitis (67%), Herpes labialis (50%), Oral syphilis (41%)
 - Necrotising Periodontitis (63.3%), Oral Candidiasis (57.1%), Necrotising Ulcerative Gingivitis (51%)
 - Oral leukoplakia (53%), Kaposi's sarcoma (46%), recurrent aphthous ulcers (44%)
 - Oral candidiasis (63.3%), Necrotising Ulcerative Periodontitis (57.1%), Necrotising Ulcerative Gingivitis (51%)
 - Linear Gingival Erythema (51%), Oral warts (50%), Angular Cheilitis (48%)
- Which of these statements is CORRECT.
Participants (45.6%) from the private dental practice were against the implementation of HIV testing at the dental workplace when compared to other oral healthcare workers' place of work for the following reasons:
 - Time constraints, lack of staff and untrained staff
 - Sensitive nature of HIV and stigmatisation by patients
 - No official HIV testing policy for the dental workplace
 - Considering rapid HIV testing in the dental workplace as an additional stress
 - All of the above
- Choose the INCORRECT statement.
The interview with Chief Director of eThekweni Department of Health indicated that:
 - policy change is not required to conduct HIV testing at the dental workplace
 - HIV counselling and testing programs to train health workers are already funded by the Department of Health
 - rapid HIV testing kits are funded and available
 - the HIV statistics data gathering process and co-ordination may be a limiting factor for implementing HIV testing at the dental workplace
 - as an incentive for offering HIV testing, private oral healthcare workers will be financially compensated by the Department of Health

Orthodontic repositioning of traumatically intruded permanent incisors - A report of three cases

- Choose the INCORRECT statement.
Which of the following statements regarding orthodontic management of intruded teeth is false?
 - Light consistent forces should be employed for repositioning
 - Greater marginal defects are observed with orthodontic repositioning
 - Lesser marginal defects are observed with orthodontic repositioning
 - Self-etch primer is preferred over traditional method of acid etching
- Choose the CORRECT answer.
Which of the following is a more biologically sound way of repositioning the intruded tooth?
 - Spontaneous re-eruption
 - Surgical repositioning
 - Orthodontic repositioning
 - All of the above
- Choose the CORRECT option.
Which of the following wires provide light forces during initial orthodontic traction?
 - Superelastic Nickel-Titanium
 - Stainless Steel
 - Beta-titanium
 - Elgiloy
- Which option is CORRECT.
What is the recommended duration of waiting for spontaneous eruption of intruded immature teeth as per IADT guidelines?
 - A few months
 - A few weeks
 - No waiting
 - None of the above

10. Choose the CORRECT percentage range. Incidence of intrusive luxation in traumatic injuries of permanent teeth is:
- 0.3 to 2%
 - 5 to 10%
 - 40 to 50%
 - 50 to 75%

A comparison of root canal transportation and centering ability between WaveOne® Gold and Protaper Next® files, using Micro-Computed Tomography

11. Choose the CORRECT statement to complete the sentence. ProTaper Next files are made up of:
- stainless steel
 - M-wire NiTi
 - heat-treated NiTi
 - carbon steel
12. Choose the CORRECT option.
With regards to number of files used, Wave One gold compared to ProTaper next uses:
- An equal number of files
 - PTN system uses small number of files
 - WOG system uses a smaller number of files
 - None of the above
13. Which of the following options is CORRECT.
Flexibility of a file depends on:
- metallurgy
 - thermal treatment
 - the size of the file
 - All of the above
14. Select the CORRECT option.
According to this study:
- WOG file produced less canal transportation
 - PTN produced less canal transportation
 - both files produced unacceptable canal transportation
 - A and C are correct
15. Which option is CORRECT.
Acceptable value of root canal transportation is:
- Between 0.15mm to .30mm
 - Up to 0.15mm
 - More than 0.15mm
 - More than .30mm

Clinical Window: What's new for the clinician?

16. The Yildirim et al. trial was a cross-over trial. This meant that:
- patients received only one intervention
 - patients received both treatments
 - patients received only placebo
 - patients received no treatment
17. In the Yildirim et al. trial, the outcome measures reported were:
- only objective
 - only subjective
 - objective and subjective
 - surrogate outcomes

18. Choose the correct option.
In the Yildirim et al. trial:
- both interventions did not reduce pain
 - both interventions were equally preferred
 - by the patients
 - patients preferred the CIS system over TA
 - patients preferred the TA intervention over CIS

19. In the Meneses-Santos et al. trial:
- both anaesthetics presented safe for controlled diabetic patients
 - lidocaine 2% was superior to prilocaine 3% for use in diabetic patients
 - lidocaine 2% was inferior to prilocaine 3% for use in diabetic patients
 - both anaesthetics were unsafe for use in controlled diabetic patients

Maxillofacial Radiology 187

20. Choose the CORRECT statement regarding the radiographs:
- Two lateral canals are visible in the incisive foramina which are named the fossae of Stenson
 - Multiple interdental nutrient canals are mostly observed in edentulous regions? T+ or F
 - The nasopalatine nerve, found in the incisive canal, is a branch of the ophthalmic division of the trigeminal nerve
 - A prominent mylohyoid ridge and deep mandibular fossa may produce an image that may be mistaken for that of osteomyelitis

ETHICS

Mandatory COVID-19 vaccination for oral health professionals (OHPs) dentists - Ethical appraisal

21. Identify the CORRECT answer.
The concept of duty of care is underpinned by this ethical principle:
- Beneficence
 - Hippocratic Oath
 - Justice
 - Autonomy
22. Which answer is CORRECT?
What circumstances would make Covid-19 vaccination by dentists supererogatory:
- Costs of vaccines, lack of medical support, misinformation
 - Falsehood, misinformation, logistical challenges
 - Lack of medical support, cultural and religious beliefs
 - Vaccines efficacy of less than 90%
23. Choose the CORRECT option.
The following statement is correct according to Kantian deontology:
- It is goodwill to vaccinate against Covid-19
 - Maximizing the benefits for other members of the society
 - It is just to vaccinate against Covid-19
 - We have a duty to vaccinate against Covid-19

24. Identify the INCORRECT statement concerning Bentham's utilitarianism as it would be applied to the Covid-19 vaccine program:
- A. The morality of Covid-19 vaccine program will be judged by how it optimizes public protection
 - B. The utility of the vaccine program is the most important measure of right or wrong
 - C. Focusses on whether the rights of participants are protected during vaccination
 - D. Is based on achieving the greatest benefit for most people

25. Identify the INCORRECT answer.
The concept of health professionals 'going beyond their call of duty' during pandemics can be seen as:
- A. Supersession
 - B. Supererogatory
 - C. Group Beneficence
 - D. Virtuous

Online CPD in 6 Easy Steps

The Continuous Professional Development (CPD) section provides for twenty general questions and five ethics questions. The section provides members with a valuable source of CPD points whilst also achieving the objective of CPD, to assure continuing education. The importance of continuing professional development should not be underestimated, it is a career-long obligation for practicing professionals.



- 1 Go to the SADA website www.sada.co.za.
- 2 Log into the 'member only' section with your unique SADA username and password.
- 3 Select the CPD navigation tab.
- 4 Select the questionnaire that you wish to complete.
- 5 Enter your multiple choice answers. Please note that you have two attempts to obtain at least 70%.
- 6 View and print your CPD certificate.

Instructions to authors



Thank you for considering the submission of your work to the Journal for possible publication. We welcome papers which may be Original Research, Clinical Review, Case Reports, Clinical Communications, Letters or Notes.

The South African Dental Journal (SADJ) is a peer reviewed, Open Access Journal, published by the South African Dental Association (SADA). The Journal primarily carries research articles which reflect oral and general health issues in Africa but also publishes papers covering the widest consideration of all health sciences. In addition, items of specific relevance to members of the Association find dissemination through the Journal. The Journal is published ten times each year in electronic format. Hard copy is available by arrangement.

We shall be obliged if your submission is prepared respecting all the details listed in these Instructions. This facilitates our process and ensures more rapid responses to you. Please use and submit the Checklist for Authors supplied on page 52 for confirmation. Thank you.

Address for submission of articles

The Editorial Assistant, Mr Dumis Ngoye,
South African Dental Journal, South African Dental Association (SADA), Private Bag 1, Houghton 2041, South Africa.
Email addresses: sadj@sada.co.za
editor@sada.co.za

Please submit the paper in electronic format in Word and Figures separately in JPEG., accompanied by a covering letter signed by the author(s).

Language

All articles must be submitted in English. Spelling should be in accord with the Shorter Oxford English Dictionary.

All articles must be submitted in English. Spelling should be in accord with the Shorter Oxford English Dictionary.

Clinical Research

Articles should adhere to the protocols of the Helsinki Declaration: (<https://www.wma.net/policies-post/wma-declaration-of-helsinki-ethical-principles-for-medical-research-involving-human-subjects/>).

Clinical Trials

Clinical trials should conform to the Consort Statement (Consolidated Statements of Reporting Trials) and Reviews to the PRISMA checklist (Preferred Reporting Items for Systematic Reviews and Meta Analyses) (<http://www.equator-network.org>).

Authors

Authors should meet the criteria for authorship as in the documents of the International Committee of Medical Journal Editors (ICMJE):

1. Substantial contributions to the conception or design of the work or the acquisition, analysis or interpretation of data for the work, AND
2. Drafting the work or revising it critically for important intellectual content, AND
3. Final approval of the version to be published, AND
4. Agreement to be accountable for all aspects of the work in ensuring that questions related to the accuracy or integrity of any part of the work are appropriately investigated and resolved (www.icmje.org).

- The front page of the manuscript should list the title of the article, the author's(s') name(s), and their qualification(s), affiliations and positions held, telephone and fax numbers and address(es), including Email address(es), if available. It is especially important that details of the Corresponding Author should be clearly stated.
- Please submit on the front page a list of up to eight Keywords.
- In the case of multiple authors, the role played and the respective contribution made by each should be recorded. For example: "Principal Researcher- 40%, Writing Article- 30%, Tissue Analysis- 20%, Microscopic Examination- 10%", etc.
- A recent requirement is that authors should be registered with ORCID. This is a number registering you as an Open Researcher and Contributor. Go to the ORCID website home page at <https://orcid.org/> and follow the Three Easy Steps indicated in green. Please submit the ORCID number with your author details.

Title

To be kept as brief, clear and unambiguous as possible.

Abstract

The abstract shall consist of not more than 200 words.

For research articles, the summary should be structured under the following headings: Introduction, Aims and Objectives, Design, Methods, Results and Conclusions. Do not include references in the Abstract.

Text

- Articles should be clear and concise.
- Text should be typed in Times New Roman font, size 11; double-spaced with a 3cm. margin on the sides, top and bottom. Each page must be clearly numbered.
- Please include electronic numbering of lines throughout the document.
- Tables should be clearly identified, using Roman numerals ie. Table I, Table II etc.
- Authors are requested to note and adhere to the current style of the Journal particularly with respect to paragraph settings and headings.

Length of the article

In general, papers should be between 4000 and 5000 words, although this is flexible. The Editor reserves the right to edit the length of an article in conjunction with the author(s) and SADJ reserves the right to charge for excess/additional pages. The first four pages of original research papers published in the SADJ will be free of charge after which a charge of R500 per page or part thereof will be levied.

Illustrations/graphics/photographs

- Illustrations/graphics/photographs must be appropriate to the content of the manuscript.
- Digital images with a DPI of at least 300 should be supplied. Photocopies and pdf. files of photographs are not acceptable.
- **Please note:** Figures should be included in the text **and** sent separately in jpg. format.
- The Figure numbers must be in Arabic numerals and clearly identified for each illustration, graphic or photograph. Please remember to record Figure numbers in the text.
- **Permission:** Where any text, tables or illustrations are used from previously published work, permission must first be ob-

tained from the holder of copyright and a copy of the agreement must be submitted with the article. Suitable acknowledgement must be recorded in the article.

Continuing Professional Development

Please supply **4-5 Multiple-choice Questions (MCQ's)** with 4 or 5 options per question related to your article. Questions must have only one correct answer, and indicate this correct answer clearly.

References

- References should be set out in the **Vancouver style** and only approved abbreviations of journal titles should be used (consult the *List of Journals Indexed in Index Medicus* for these details at: <http://www.nlm.nih.gov/tsd/serials/lji.html>).
- References should be inserted seriatim in the text using superscript numbers and should be listed at the end of the article in numerical order.
- A reference in the text should appear as indicated: "...as the results of a previous study showed.²³"
- Where there are several papers referenced, the superscript numbers would appear as: "...previous studies have shown.^{3,5,7,9-12,14}"
- Do not list the references alphabetically.**
- It is the author's responsibility to verify each reference from its original source. Please note that an article may be rejected if the referencing is inaccurate.
- Names and initials of all authors should be given unless there are more than six, in which case the first three names should be given, followed by 'et al'. First and last page numbers should be given. Where it is applicable the page numbers should be abbreviated by omitting redundant numbers eg. pages 456 to 478 is recorded as 456-78, and 456 to 459 as 456-9, but 398 to 401 is recorded as 398-401.
- Notice that volume numbers are not given in bold, authors are not linked by 'and' or '&', and the year of publication appears after the name of the journal. No item should appear in italics except for foreign terms, eg *in vivo*.

Journal references should appear thus:

Smith NC, Haines A. The role of the dentist in public health promotion. *Br Dent J*. 1983; 298: 249-51.

Book references should be set out as follows:

Terblanche N. Principles of Periodontology, 4th ed. London: Butterworth, 1985: 96-101.

Weinstein L, Swartz MN. Pathogenic properties of invading microorganisms. In: Sodeman WA, Smith RT, eds. *Pathologic Physiology: Mechanisms of Disease*. Philadelphia: WB Saunders, 1974: 457-72.

Manuscripts accepted but not yet published may be included as references followed by the words 'in press'.

'Unpublished observations' and 'personal communications' may be cited in the text but not in the reference list.

Declaration

All sources of funding, possible financial interest/s or incentives in products or services mentioned in the article must be disclosed. Authors are kindly requested to read and sign the attached declaration on page 51.

No articles that have been published previously, or that are currently being considered for publication elsewhere, will be accepted. Authors are kindly requested to verify that their article complies with this condition.

Ethics

Where relevant, authors should indicate whether their research has been approved by the Ethics Committee of their Institution or by other research ethics committees.

Conflict of interest

Authors must disclose their involvement with any company either owned by them or from which they have received a grant or remuneration or with which they have an association, and must declare any other personal interest they may have which would constitute a Conflict of Interest. These may include personal relationships, academic competition, or intellectual beliefs. Should there be no applicable Conflicts of Interest this should also be so stated. The statement will be included at the end of the text.

Copyright

The South African Dental Journal is a peer reviewed, Open Access Journal, adhering to the Budapest Open Access Initiative: "By 'open access' to this literature, we mean its free availability on the public internet, permitting any users to read, download, copy, distribute, print, search, or link to the full texts of these articles, crawl them for indexing, pass them as data to software, or use them for any other lawful purpose, without financial, legal, or technical barriers other than those inseparable from gaining access to the internet itself. The only constraint on reproduction and distribution, and the only role for copyright in this domain, should be to give authors control over the integrity of their work and the right to be properly acknowledged and cited." <https://access.okfn.org/definition/index.html>

The Managing Editor reserves the right to decline articles, photographs or illustrations where products or services are mentioned that are not appropriate.

Submission

The paper should be submitted in one file including all Tables and Figures and their accompanying Legends. Figures should also be submitted separately file in JPEG. format.

Please submit the paper in electronic format in Word along with separate Figures in JPEG. format to: sadj@sada.co.za and to neil.wood@smu.co.za, accompanied by a covering letter and the Declaration on page 51 signed by all the author(s).

Galley proofs

Changes/corrections to the proofs supplied to authors **must** be returned to the publishers by email or by fax and not over the telephone. Galley proofs must please be returned to the publishers within **four days** after receipt thereof.

Editorial Policy

Authors may also wish to refer to the Editorial Policy of the SADJ available on the SADA website.

Enquiries

Enquiries regarding Journal matters can be directed to Mr Dumi Ngoepe, Editorial Assistant, at SADA headquarters on: Tel: +27 (0)11 484 5288, Fax: +27 (0)11 642 5718, Email: sadj@sada.co.za

Declaration by Author/s

Title: _____

Author/s: _____

I/We, the undersigned confirm and declare that:

1. This manuscript is my/our original work and I am/we are the owner/s of this manuscript and possess rights of copyright.
2. I/we confirm that this manuscript has not been published previously and it is not currently considered for publication elsewhere. Has this article been submitted to any other journal and if so, has it been rejected?
YES **NO**
3. For no consideration or royalty, I/we hereby assign, transfer and make over to SADA all the rights of copyright, which have or will come into existence in relation to this manuscript.
4. I/we waive in favour of SADA or any successors in title any moral rights which may be vested in me/us.
5. The manuscript does not constitute an infringement of any copyright and I/we indemnify SADA against all loss or damage, from any cause arising which SADA may sustain as a result of having been granted copyrights to the manuscript.
6. The research has been approved by the Ethics Committee of my/our institution/s or the Ethics Committee/s of other accredited research facilities.
7. I/we have disclosed in my/our Acknowledgments all sources of funding, possible financial interest/s or incentives in products or services mentioned in the paper.

..... Initial(s) and Surname Signature Date
..... Initial(s) and Surname Signature Date
..... Initial(s) and Surname Signature Date
..... Initial(s) and Surname Signature Date
..... Initial(s) and Surname Signature Date
..... Initial(s) and Surname Signature Date



Author's Checklist

- | | |
|--|--------------------------|
| Have you read the Instructions to Authors? | <input type="checkbox"/> |
| Are you submitting electronically? | <input type="checkbox"/> |
| Have you provided all author information including first names, affiliations, qualifications, positions held, Department and Institution, ORCID number, contact details? | <input type="checkbox"/> |
| Is the first author under the age of 35 on submission of the article? | <input type="checkbox"/> |
| Have you provided all details of the Communicating Author? | <input type="checkbox"/> |
| Have you submitted questions for the CPD section? (four or five multiple choice, one correct answer)? | <input type="checkbox"/> |
| Have you submitted details of the contribution of each author... can be percentage or descriptive... or both? | <input type="checkbox"/> |
| Have you confirmed the status of your paper in terms of any Conflict of Interest? | <input type="checkbox"/> |
| Have you submitted the Clearance Certificate number when Ethical permission has been required to undertake research or to publish data? | <input type="checkbox"/> |
| Does the paper adhere to the format requested in Instructions to Author? | <input type="checkbox"/> |
| Are the references quoted according to Journal policy, both in the text and in the list of references? | <input type="checkbox"/> |
| Have all authors signed the Letter of Submission? | <input type="checkbox"/> |



Smalls advertising and placement procedure

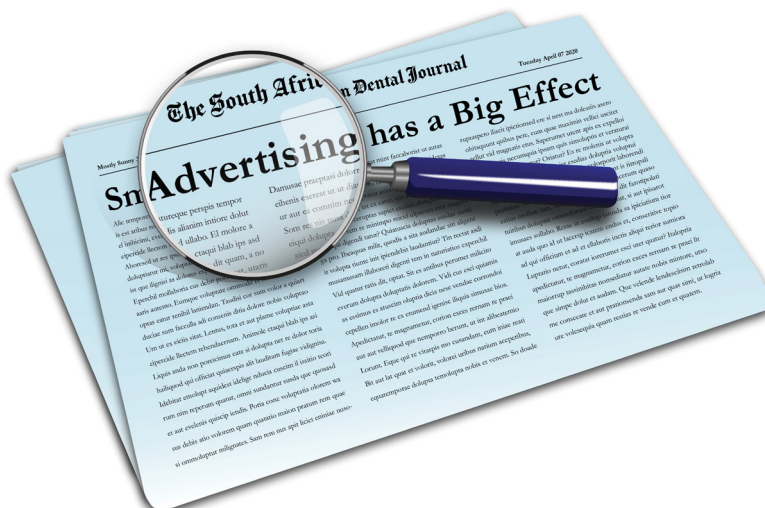- All smalls advertisements are restricted to a **maximum 100 words** per advertisement.
- All advertisement requests are required in writing, **submit to abayman@sada.co.za**, with full contact details of the advertiser which should include:
 - ◆ the wording of the advertisement as you require it to be published;
 - ◆ the members professional number; (will not be published);
 - ◆ the members contact details (will not be published).
- Advertisement **lifespan is two weeks** from the date of upload.
- Advertisements to be **repeated follow the same process** as the original placement request.
- All advertisements which **exceed a word count of 100** words will be forwarded to our **publishers E-Doc** for further processing as a potential advertisement to be placed in the SADJ electronically or as website advertising. E-Doc will contact you thereafter regarding your requirements.
- **SADA Members** may place advertisements at no cost providing their annual membership fees are either paid in full at the time of their request of a debit order request has been lodged.
- **Non-SADA Member** advertisers will be charged R25 per word for placement of their advertisements.
- Advertisement must be paid in full prior to uploading on the web platform.
- Invoice may be settled telephonically with the use of a credit card to prevent delay of placement.
- **Telephonically processed** payments will result in uploading of advertisement within **24 hours** of settlement.
- Advertiser remains liable for placement costs should payment be dishonoured and invoice remains unpaid.

Contact details:

Ann Bayman
 South African Dental Association
 Tel: +27 (0)11 484 5288
 Email: marketing@sada.co.za

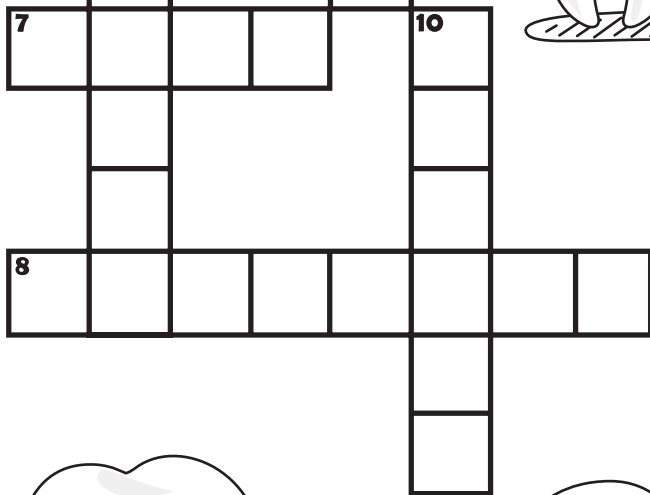
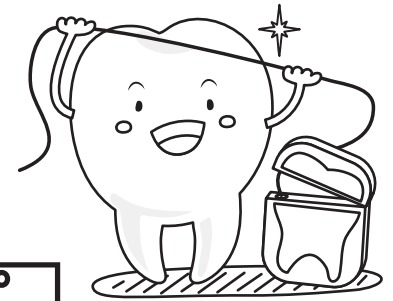
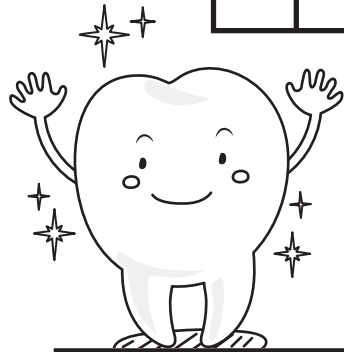
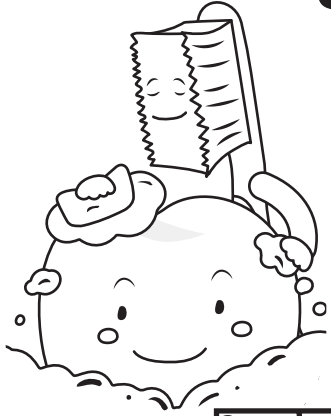

www.sada.co.za



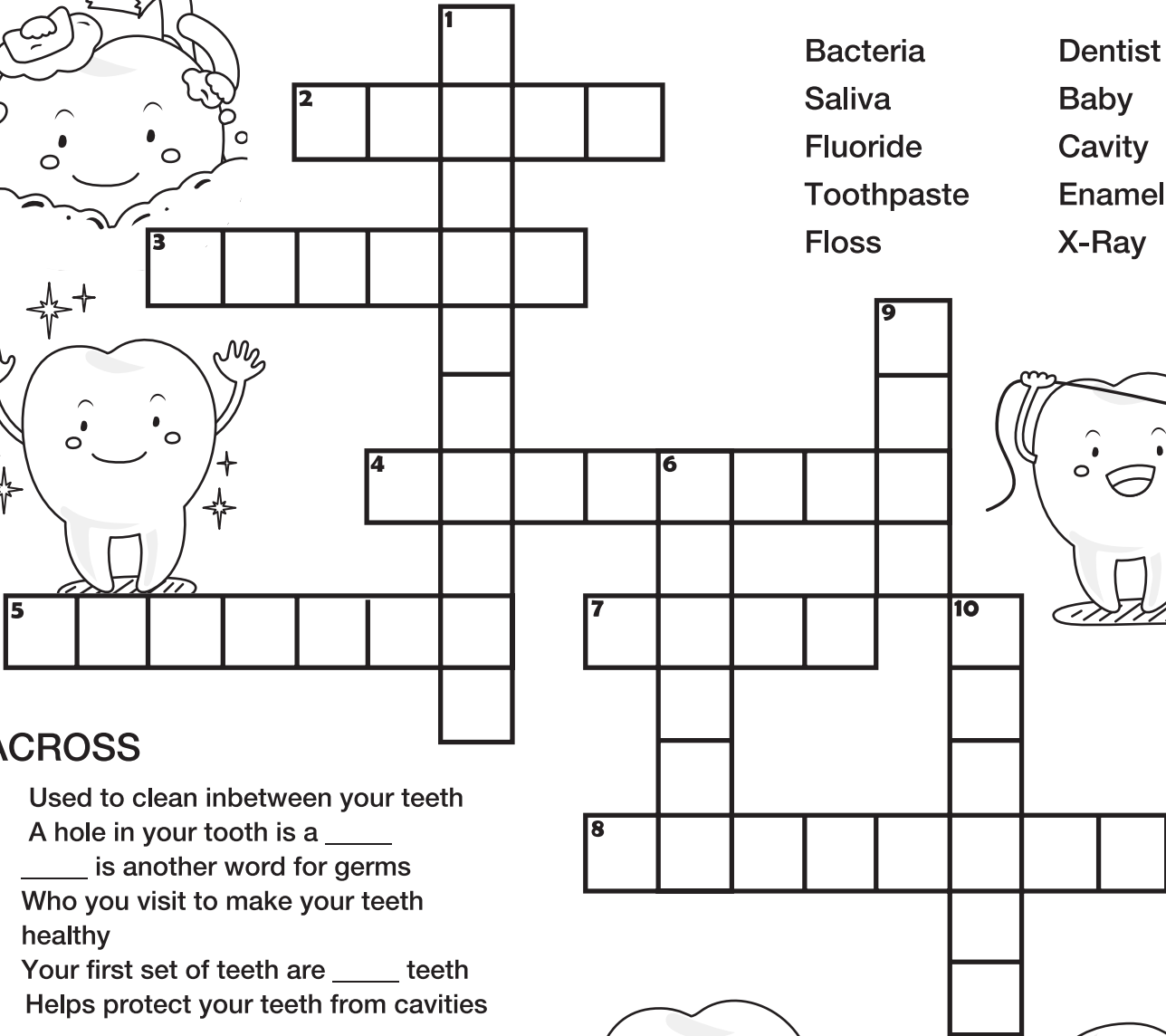
Children's Dental Month

CROSSWORD PUZZLE



WORD BANK

- | | |
|------------|---------|
| Bacteria | Dentist |
| Saliva | Baby |
| Fluoride | Cavity |
| Toothpaste | Enamel |
| Floss | X-Ray |



ACROSS

- Used to clean inbetween your teeth
- A hole in your tooth is a _____
- _____ is another word for germs
- Who you visit to make your teeth healthy
- Your first set of teeth are _____ teeth
- Helps protect your teeth from cavities


DOWN

- What you put on your toothbrush in order to clean your teeth
- The hard outer layer of your teeth
- What a dentist uses to inspect teeth
- _____ helps to break down food while washing your teeth and gums

February is National Children's Dental Health Month | www.sada.co.za, +27 11 484 5288, info@sada.co.za

HEALTHY SMILE TIPS

- Brush your teeth twice a day with a fluoride toothpaste.
- Clean between your teeth daily.
- Eat a healthy diet that limits sugary beverages and snacks.
- See your dentist regularly for prevention and treatment of oral disease.



SADA

